

*Full Length Research Paper*

# A study on the evaluation of the anti-ulcerogenic activity of hyaluronic acid against ethanol induced gastric mucosal injury in rats

Yatim R.A, Rais B.B and Shah N.S

Department of Biochemistry, Faculty of Medicine, International Islamic University  
Malaysia, ombak, Selangor, Malaysia.

Accepted 01 January, 2020

The present study was performed to evaluate the anti-ulcerogenic activity of hyaluronic acid against ethanol induced gastric mucosal injury in rats. Four groups of adult *Sprague Dawley* rats were orally pre-treated respectively with distilled water (ulcer control groups), omeprazole (reference group), high molecular weight hyaluronic acid and 0.8% hyaluronic acid gel (experimental groups) one hour before oral administration of absolute ethanol to generate gastric mucosal. After an additional hour, the rats were sacrificed and the ulcer areas of the gastric walls were determined. Grossly, the ulcer control group exhibited severe mucosal injury, whereas pre-treatment with omeprazol, and both types of hyaluronic acid gel, exhibited significant protection of gastric mucosal injury. Histological studies of the gastric wall revealed that ulcer control group exhibited severe damage of gastric mucosa; along with edema and leucocytes infiltration of submucosal layer compared to rats pre-treated with hyaluronic acid gels which showed comparatively gastric mucosal protection, reduction or absence of edema and leucocytes infiltration of submucosal layer. The present finding suggests that high molecular weight hyaluronic acid gel promotes higher ulcer protection.

**Key words:** Hyaluronic acid gel, cytoprotection, gastric ulcer, histology.

## INTRODUCTION

Hyaluronic acid is a major component of the extracellular matrix of many tissues composed of repeating disaccharides of D-glucuronic acid and N-acetyl-glucosamine which makes up a large non sulfated glycosaminoglycan (Toole et al., 1989). Fibroblasts are the major components which secrete hyaluronic acid into the extracellular matrix (Mesa et al., 2002).

Hyaluronidase is able to break down the proteoglycans in the ground substance of connective tissues. High molecular weight hyaluronic acid can therefore perform an efficient anti hyaluronidase action as a result of its physiological macro-aggregating activity. Hyaluronic acid also plays an important role in tissue repair and protective effect. Under normal conditions, the proteoglycans in the ground substance of the mucosa connective tissue represents an effective barrier against bacterial invasion and against the spread of bacterial

toxins. If this barrier is damaged, topical application of high molecular weight hyaluronic acid can help reconstruct the barrier due to its macro-aggregating effect on the proteoglycans. The macro-aggregating effect of hyaluronic acid in proteoglycans inhibits formation of edema and which is also known as anti-oedema-tigeneous effect (Pagnacco et al., 1997).

During initial stage of inflammation, hyaluronic acid is secreted by the body as a natural tissue response to work against the harmful action of bacterial hyaluronidase and edema formation (Weigel et al., 1986). Hyaluronic acid level in the body rising up immediately during embryonic development (Kujawa et al., 1986), wound healing process (AL-Bayaty et al., 2010; Fraser and Laurent, 1989) and tumour development (Knudson et al., 1989). The protective effects of hyaluronic acid are so diverse which makes it useful as anti-inflammatory and antiedematous agent.

The efficacy of hyaluronic acid in reducing epithelial cells proliferation depends on its molecular weight and concentration (Mesa et al., 2002). These findings are parallel with the previous data published by Laurent et

\*Corresponding author. E-mail: [research\\_yatim@yahoo.com](mailto:research_yatim@yahoo.com).

al. (1995). They claimed that the hyaluronic acid was able to act as an anti-inflammatory agent by scavenging prostaglandin, metalloproteinase and other bio-active molecules, thus reducing the level of inflammatory mediators.

Gingival gel based on hyaluronic acid, providing active protection from gum disease (AL- Bayaty et al., 2010) and support for the natural healing of inflamed and damaged tissue in the mouth (Pirnaza et al., 1999). Hyaluronic acid is a natural substance found in the connective tissues of the body (Moseley et al., 2002). When applied to gums; it stimulates the production of healthy new tissue. It has been used for years by physicians to boost regrowth of connective tissue throughout the body (Jentsh et al., 2003). Thus far, there is no data available on gastroprotective activity of hyaluronic acid. The present study was undertaken to evaluate anti-ulcerogenic properties of hyaluronic acid in rats.

## MATERIALS AND METHODS

### Omeprazole

Omeprazole is a proton pump inhibitor which has been widely used as acid inhibitor agents for the treatment of disorders related to gastric acid secretion for about 15 years (Li et al., 2004). Omeprazole is substituted benzimidazoles and it inhibit acid

secretion by acting on the hydrogen-potassium exchanger ( $H^+ : K^+$ -ATPase) for the apical plasma membrane of the gastric mucosa (Sato et al., 1989). Omeprazole is highly selective for the proton pump and undergo catalyzed conversion into active form within the acid forming space. The active inhibitors react with SH (thiol) group of the proton pump, resulting in inhibition of acid formation (Nagaya et al., 1991). In this study, omeprazole was used as the reference anti-ulcer drug, and was obtained from the University Malaya Medical Centre (UMMC) Pharmacy. The drug was dissolved in distilled water and administered orally to the rats in concentrations of 20 mg/kg body (5 ml/kg) (Pedernera et al., 2006).

### Hyaluronate gel

Two types of gingival gel hyaluronic acid based used in this study, high molecular weight hyaluronic acid 240 mg/100 g and 0.8% hyaluronic acid gel. Gels were obtained from the dental supplier (Manufactured by Bioplax limited London –UK) and administered orally to rats (5 ml/kg body weight)

### Experimental animals

*Sprague Dawley* healthy adult male rats were obtained from the Experimental Animal House, Faculty of Medicine, University of Malaya; the rats were divided randomly into 4 groups of 6 rats. Rat weighted between 200 to 225 g was placed individually in separate cage (one rat per cage) with wide- mesh wire bottoms to prevent coprophagia during the experiment. The animals were maintained on standard pellet diet and tap water. The study was approved by the Research Committee on the Ethical Use of Animal in Research (UiTM Care) University Teknologi, Mara. Throughout the experiments, all animals received human care according to the criteria outlined in the —Guide for the Care and Use of laboratory Animals prepared by the National Academy of Sciences and

published by the National Institute of Health.

### Gastric ulcer-induction by ethanol and tissue sample collection

The rats were fasted for 48 h before the experiment (Garg et al., 1993), but were allowed free access drinking water up till 2 h before the experiment. Gastric ulcer in *Sprague Dawley* rats was induced by orogastric intubation of absolute ethanol (5 ml/kg) according to the method described by De Pasquale et al. (1995) with slight modification. Control groups were orally administered with distilled water (5 ml/kg). The reference group was received oral doses of 20 mg/kg omeprazole in distilled water (5 ml/kg) as positive controls. Experimental groups were orally administered with high molecular weight hyaluronic acid 240 mg/100 g and 0.8% hyaluronic acid gel (5 ml/kg) each, respectively. One hour after this pre- treatment; all groups of rats were gavaged with absolute ethanol (5 ml/kg) in order to induce gastric ulcers (Hollander et al., 1985). The rats were euthanized by cervical dislocation 60 min later (Paiva et al., 1998) under over dose of diethyl ether anesthesia and their stomachs were immediately excised.

### Gross gastric lesions evaluation

Any ulcers would be found in the gastric mucosa, appearing as elongated bands of hemorrhagic lesions parallel to the long axis of the stomach. Each gastric mucosa was thus examined for damage. The length (mm) and width (mm) of the ulcer on the gastric mucosa were measured by a planimeter ( $10 \times 10 \text{ mm}^2 = \text{ulcer area}$ ) under dissecting microscope ( $\times 1.8$ ). The area of each ulcer lesion was measured by counting the number of small squares,  $2 \times 2 \text{ mm}$ , covering the length and width of each ulcer band. The sum of the areas of all lesions for each stomach was applied in the calculation of the ulcer area (UA) wherein the sum of small squares  $\times 4 \times 1.8 = \text{UA mm}^2$ ) as described by Kauffman and Grossman (1978) with slight modification. The inhibition percentage (I%) was calculated by the following formula as described by Njar et al. (1995) with slight modification.

$$(I\%) = [(UA_{\text{control}} - UA_{\text{treated}}) \div UA_{\text{control}}] \times 100\%.$$

### Histological evaluation of gastric lesions

Specimens of the gastric walls from each rat were fixed in 10% buffered formalin and processed in a paraffin tissue processing machine. Sections of the stomach were made at a thickness of 5  $\mu$  and stained with hematoxylin and eosin for histological evaluation.

### Statistical analysis

All values were reported as mean  $\pm$  S.E.M. The statistical significance of differences between groups was assessed using one-way ANOVA. A value of  $p < 0.05$  was considered significant.

## RESULTS

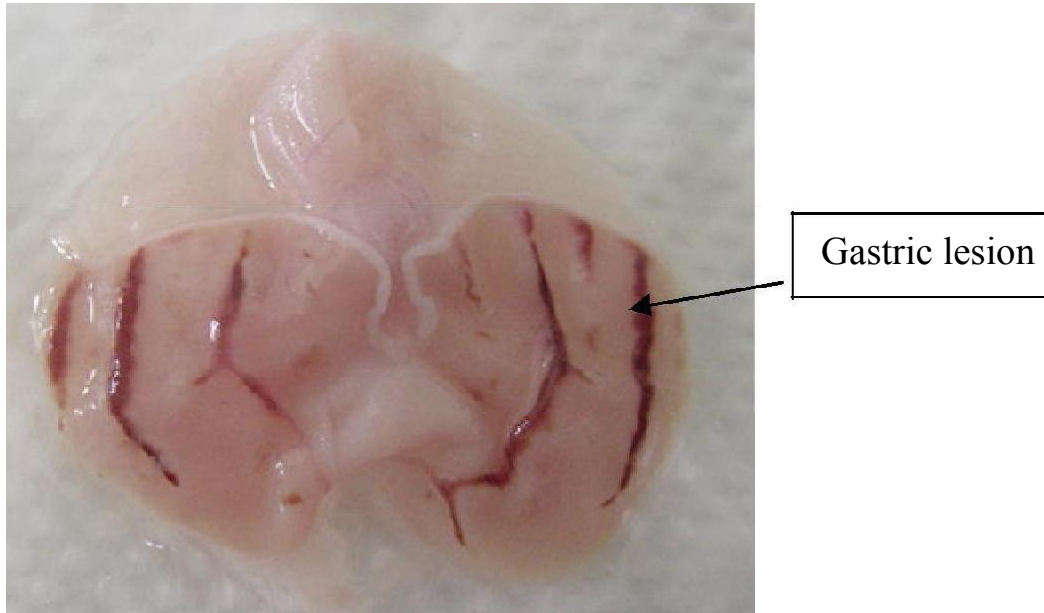
### Gross evaluation of gastric lesions

The anti-ulcer activity of high molecular weight hyaluronic acid 240 mg/100 g and 0.8% hyaluronic acid gel in ethanol-induced gastric lesion model is reported in Table

**Table 1.** Observed ulcer area and inhibition percentage in rats.

Animal group	Pre-treatment (5 ml/kg dose)	Ulcer area (mm) <sup>2</sup> (Mean ± S.E.M)	Inhibition (%)
1	Distilled water (Ulcer control)	920.00 ± 11.76 <sup>a</sup>	-
2	Omeprazole (20 mg/kg)	213.00 ± 11.25 <sup>u</sup>	76.85
3	0.8% hyaluronic acid gel	125.80 ± 6.98 <sup>e</sup>	86.33
4	high molecular weight hyaluronic acid gel 240 mg/100 g	45.20 ± 2.89 <sup>t</sup>	95.09

All values are expressed as mean ± standard error mean. Means with different superscripts are significantly different. The mean difference is significant at the 0.05 level.



**Figure 1a.** Gross appearance of the gastric mucosa in a rat pre-treated with 5 ml/kg of distilled water (negative control). Severe injuries are seen in the gastric mucosa.

1. Results showed that rats pre-treated with hyaluronic acid gels before being given absolute alcohol had significantly reduced areas of gastric ulcer formation compared to rats pre-treated with only distilled water (ulcer control group) (Figures 1a, b and c). Moreover, the hyaluronic acid gel significantly suppressed the formation of the ulcers and it was interesting to note the flattening of gastric mucosal folds in rats pretreated with high molecular weight hyaluronic acid gel. It was also observed that protection of gastric mucosa was more prominent in rats pre-treated high molecular weight hyaluronic acid gel (Table 1). The significant inhibition of gastric ulcer in group pretreatment with hyaluronic acid gel was compared with omeprazole which is a standard drug used for curing gastric ulcer.

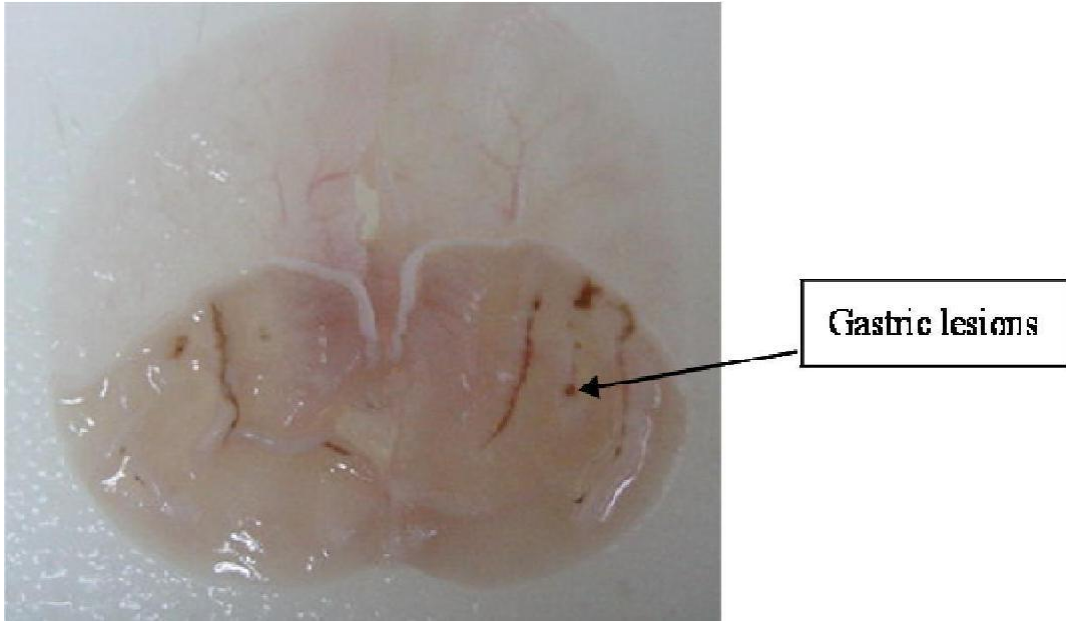
### Histological evaluation of gastric lesions

Histological observation of ethanol induced gastric

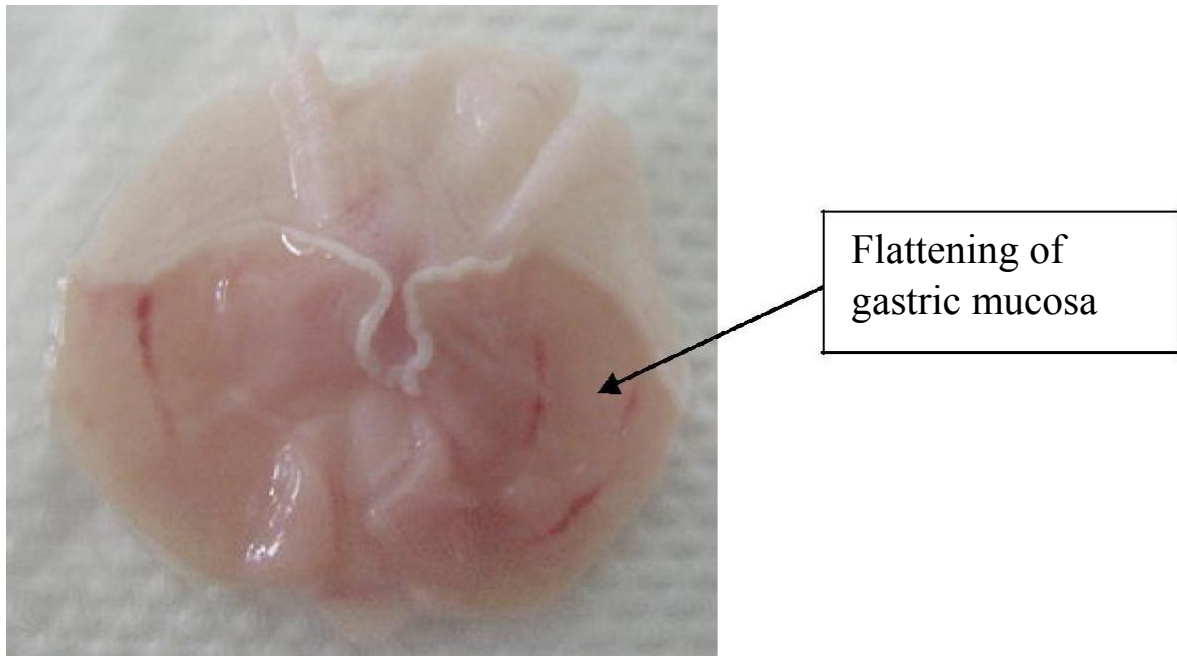
lesions in ulcer control group pre-treated with only distilled water showed comparatively extensive damage to the gastric mucosa, and oedema and leucocytes infiltration of the submucosal layer (Figure 1d). Rats that received pre-treatment with hyaluronic acid gel had comparatively better protection of the gastric mucosa as seen by reduction in ulcer area, reduced or absence of submucosal oedema and leucocytes infiltration (Figure 1e and f). The hyaluronic acid gel has been shown to exert the cytoprotective effects and was more prominent in high molecular weight hyaluronic acid gel.

### DISCUSSION

Peptic ulcers are caused when the natural balances between the aggressive factors of acid and pepsin and defensive mechanisms of mucus, bicarbonate, mucosal turnover and blood supply (mucosal barrier) are disturbed (Piper and Stiel, 1986). Baron et al. (1980) have



**Figure 1b.** Gross appearance of the gastric mucosa in a rat pre-treated with 5 ml/kg of omeprazole (20 mg/kg). Injuries to the gastric mucosa are milder compared to the injuries seen in the negative control rat.

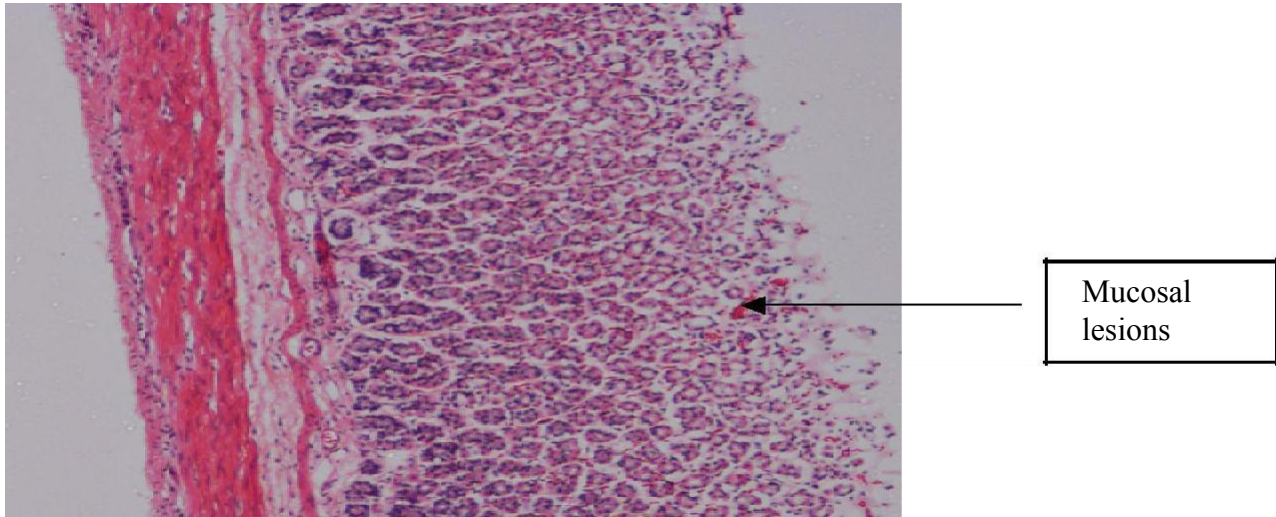


**Figure 1c.** Gross appearance of the gastric mucosa in a rat pre-treated with 5 ml/kg of gengigel bag. Very few injuries to the gastric mucosa are seen, and showed flattening of gastric mucosa.

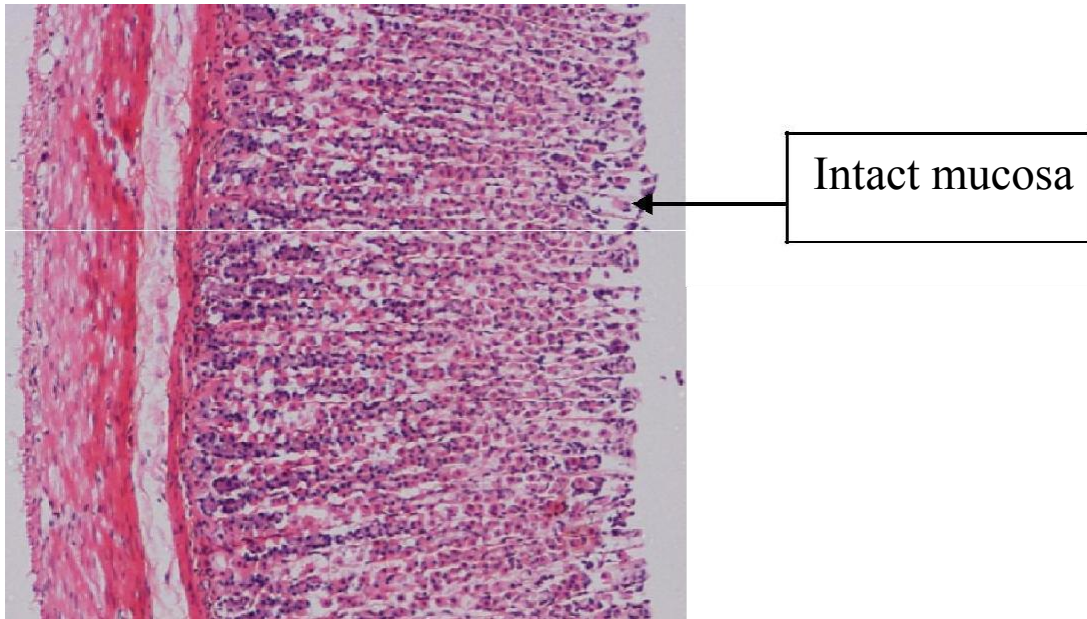
suggested that acid and pepsin are relatively less important as causative agents and that a defect in the defensive mechanism of gastric mucosa is the first step toward ulcer formation. Although in most cases the etiology of ulcer is unknown, it is generally accepted that

it is the result of an imbalance between aggressive factors and maintenance of the mucosal integrity through the endogenous defense mechanism (Piper and Stiel, 1986). It is known that gastric lesions produced by ethanol). administration appeared as multiple-hemorrhagic





**Figure 1e.** Histological section of gastric mucosa in a rat pre-treated with 5 ml/kg of omeprazole (20 mg/kg). There is mild disruption to the surface epithelium with mild edema and leucocytes infiltration of the submucosal layer (H and E stain 10 $\times$ ).



**Figure1f.** Histological section of gastric mucosa in a rat pre-treated with 5 ml/kg of gengigel bag. There is no disruption to the surface epithelium with no edema and no leucocytes infiltration of the submucosal layer (H and E stain 10 $\times$ ).

red bands of different size along the glandular stomach. Ethanol is commonly used for inducing ulcer in experimental rats and lead to intense gastric mucosal damage. Studies suggest that the ethanol damage to the gastrointestinal mucosa starts with microvascular injury, namely disruption of the vascular endothelium resulting in increased vascular permeability, edema formation and epithelial lifting (Szabo et al., 1995). Ethanol produces necrotic lesions in the gastric mucosa by its direct toxic

effect, reducing the secretion of bicarbonates and production of mucus (Marhuenda et al., 1993). Exposure to ethanol increases the extension of cellular damage in a dose-dependent way (Mutoh et al., 1990).

Oxidative stress plays an important role in the pathogenesis of various diseases including gastric ulcer, antioxidants being reported to play a significant role in the protection of gastric mucosa against various necrotic agents (Trivedi and Rawal, 2001). Antioxidants could

help to protect cells from damage caused by oxidative stress while enhancing the body's defense systems against degenerative diseases. Administration of antioxidants inhibits ethanol-induced gastric injury in rat (Ligumsky et al., 1995).

Numerous literature data indicate that hyaluronic acid has an effect on immune cells and suggest its role as a regulator of the inflammatory process (Krasinski and Tchorzewski, 2007; Stern et al., 2006).

Several studies indicate the antioxidant properties of HA (Campo et al., 2008; Zhao et al., 2008). Hyaluronic acid can reduce tissue injury caused by reactive oxygen intermediates (ROIs) by creating a mechanical barrier that limits the access of ROIs to the cell surface and reduces DNA damage and NF- $\kappa$ B and caspase activation (Campo et al., 2008; Zhao et al., 2008; Campo et al., 2004).

However, the mechanism by which this glycosaminoglycan affects respiratory burst in professional phagocytes has not been clearly explained. Besides its ability to scavenge reactive oxygen intermediates (ROIs) in the extracellular space, its direct effect on oxygen metabolism was suggested (Lym et al., 2004; Suzuki and Yamaguchi, 1993).

This hypothesis is supported by the observation that hyaluronic acid, synergistically with TGF- $\beta$ 2, induces the p47phox NADPH oxidase component in promyelocytic cells (Basoni et al., 2006).

Hyaluronic acid can scavenge the reactive oxygen species (super-oxide anions) and free radicals produced by ethanol. These reactive intermediates are potentially implicated in ulcerogenicity (Lym et al., 2004; Suzuki and Yamaguchi, 1993).

The result of the present study revealed protection of gastric mucosa and inhibition of leucocytes infiltration of gastric wall in rats pretreated with hyaluronic acid gel. Similarly, Kobayashi et al. (2001) reported that teprenone exerts a protective effect against mucosal lesions through inhibition of neutrophils infiltration in the ulcerated gastric tissue. Shimizu et al. (2000) demonstrated that the reduction of neutrophils infiltration into ulcerated gastric tissue promotes the healing of gastric ulcers in rats. Cheng and Koo (2000) showed that oral administration of plant extract before ethanol administration significantly decreased neutrophils infiltration of gastric mucosa and Fujita et al. (1998) observed that an increase in neutrophils infiltration into ulcerated gastric tissue delayed the healing of gastric ulcers in rats. Absolute alcohol would extensively damage the gastric mucosa leading to increased neutrophils infiltration into the gastric mucosa. Oxygen free radicals derived from infiltrated neutrophils in ulcerated gastric tissues have inhibitory effect on gastric ulcers healing in rats (Suzuki et al., 1998). Neutrophils mediate lipid peroxidation through the production of superoxide anions (Zimmerman et al., 1997). Neutrophils are a major source of inflammatory mediators and can release potent reactive oxygen

species such as superoxide, hydrogen peroxide and myeloperoxidase derived oxidants. These reactive oxygen species are highly cytotoxic and can induce tissue damage (Cheng and Koo, 2000). Furthermore, neutrophils accumulation in gastric mucosa has been shown to induce microcirculatory abnormalities (Bou-Abboud et al., 1988). Suppression of neutrophils infiltration during inflammation was found to enhance gastric ulcer healing (Tsukimi et al., 1996). Several studies have demonstrated that the effect of hyaluronic acid on immune cells is dependent on its molecular weight. The high-molecular-weight form possesses anti-inflammatory properties which act through the inhibition of phagocytosis, cytokine production, and cytokine gene expression or intensification of the suppressor activity of regulatory T cells (Bollyky et al., 2007; Forrester and Balazs, 1980; Schimizzi et al., 2006).

It is speculated that the gastroprotective nature exerted by hyaluronic acid could be attributed to its anti-inflammatory activity. This anti-inflammatory activity could also be a key factor in the prevention of gastric ulcer as reported by Swarnakar et al. (2005).

In the present study, we observed flattening of the mucosal folds which suggests that gastroprotective effect of hyaluronic acid might be due to a decrease in gastric motility. It is reported that the changes in the gastric motility may play a role in the development and prevention of experimental gastric lesions (Garrick et al., 1986; Takeuchi et al., 1987). Relaxation of circular muscles may protect the gastric mucosa through flattening of the folds. This will increase the mucosal area exposed to necrotizing agents and reduce the volume of the gastric irritants on rugal crest (Takeuchi and Nobuhara, 1985). Ethanol produces a marked contraction of the circular muscles of rat fundic strip. Such a contraction can lead to mucosal compression at the site of the greatest mechanical stress, at the crests of mucosal folds leading to necrosis and ulceration (Mersereau and Hinchey, 1982).

## Conclusion

Hyaluronic acid gel could significantly protect the gastric mucosa against ethanol-induced injury. Such protection was ascertained by the reduction of ulcer areas in the gastric wall as well as the reduction or inhibition of edema and leucocytes infiltration of submucosal layers, and protection was most prominent in high-molecular-weight form.

## ACKNOWLEDGMENTS

The authors express gratitude to the staff of the Faculty of Medicine Animal House for the care and supply of rats,

and to the University Teknologi Mara for the financial support DANA Grant 5/3/DST (11/09) 2009.

## REFERENCES

- AL-Bayaty F, Abdulla M, Abu Hassan MI, Masud MI (2010). Wound Healing Potential by Hyaluronate Gel in Streptozotocin-induced Diabetic Rats. *Sci. Res. Essays*, 5(18): 2756-2760.
- AL Bayaty F, Taiyeb-ali T, Abdulla MA, Hashim F (2010). Antibacterial effect of chlorine dioxide and hyaluronate on dental biofilm. *Afr. J. Microbiol. Res.*, 4(14): 1525-1531.
- Baron TH, Langman MTS, Wastell C (1980). Stomach and duodenum. In: I.A.D/ Bouchier (Ed.), *Recent Advances in Gastroenterology*. Churchill Livingstone, London, pp. 23-29.
- Basoni C, Reuzeau E, Croft D, Genot E, Kramer IM (2006). CD44 and TGF $\beta$ 1 synergise to induce expression of a functional NADPH oxidase in promyelocytic cells. *Biochem. Biophys. Res. Commun.*, 343: 609-616.
- Bollyky PL, Lord JD, Masewicz SA, Evanko SP, Buckner JH, Wight TN, Nepom GT (2007). High molecular weight hyaluronan promotes the suppressive effects of CD4+ CD25+ regulatory T cells. *J. Immunol.*, 179: 744-747.
- Bou-Abboud CF, Wayland H, Panlsen G, Guth PH (1988). Microcirculatory stasis precedes tissue necrosis in ethanol-induced gastric mucosal injury in rat. *Dig. Dis. Sci.*, 33: 872-877.
- Campo GM, Avenoso A, Campo S, D'Ascola A, Traina P, Sama D, Calatroni A (2008). NF- $\kappa$ B and caspases are involved in the hyaluronan and chondroitin-4-sulphate-exerted antioxidant effect in fibroblast cultures exposed to oxidative stress. *J. Appl. Toxicol.*, 28: 509-517.
- Campo GM, Avenoso A, Campo S, D'Ascola A, Traina P, Calatroni A: Chondroitin-4-sulphate inhibits NF- $\kappa$ B (2008). Translocation and caspase activation in collagen-induced arthritis in mice. *Osteoarthr. Cartil.*, 16: 1474-1483.
- Campo GM, Avenoso A, Campo S, D'Ascola A, Ferlazzo AM, Calatroni A (2004). Reduction of DNA fragmentation and hydroxyl radical production by hyaluronic acid and chondroitin-4-sulphate in iron plus ascorbate-induced oxidative stress in fibroblast cultures. *Free Radic. Res.*, 38: 601-611.
- Cheng CL, Koo MWL (2000). Effect of *Centella asiatica* on ethanol induced gastric mucosal lesions in rats. *Life Sci.*, 67: 2647-2653.
- De Pasquale R, Germano MP, Keita A, Sanogo R, Lauk L (1995). Antilucer activity of *Pteleopsis suberosa*. *J. Ethnopharmacol.*, 47: 55-58.
- Fraser JR, Laurent TC (1989). Turnover and metabolism of hyaluronan. In: *The biology of hyaluronan*. Chiba Foundation Symp. Chichester Wiley, 143: 41-59.
- Forrester JV, Balazs EA (1980). Inhibition of phagocytosis by high molecular weight hyaluronate. *Immunol.*, 40: 435-446.
- Fujita H, Takahashi S, Okabe S (1998). Mechanism by which indomethacin delays the healing of acetic acid-induced ulcers in rats. Role of neutrophils antichemotactic and chemotactic activities. *J. Physiol. Pharmacol.*, 49: 71-82.
- Garg GP, Nigam SK, Ogle CW (1993). The gastric antiulcer effects of the leaves of the neem tree. *Planta Medica*, 59: 215-217.
- Garrick T, Buack S, Bass P (1986). Gastric motility is major factor in cold, restraint induced lesion formation in rats. *Am. J. Physiol.*, 250: 6191-6199.
- Hollander D, Taranawski A, Krause WJ, Gergely H (1985). Protective effect of sucralfate against alcohol- induced gastric mucosal injury in the rat. *Gastroenterol.*, 88: 366-374.
- Jentsh H, Pomowski R, Kundt G, Gocke R (2003). Treatment of gingivitis with hyaluronan. *J. Clin. Periodontol.*, 30: 159-164.
- Kauffman GL, Grossman MI (1978). Prostaglandin and cimetidine inhibit the formation of ulcers produced by parenteral salicylates. *Gastroenterol.*, 75: 1099-1102.
- Knudson W, Biswas C, Li XQ, Nemecek RE, Toole BP (1989). Turnover and metabolism of hyaluronan. In: *The biology of hyaluronan*. Chiba Foundation Symp. Chichester: Wiley, 143: 150-169.
- Kobayashi T, Ohta Y, Yoshino, J, Nakazawa S (2001). Teprenone promotes the healing of acetic acid-induced chronic gastric ulcers in rats by inhibiting neutrophil infiltration and lipid peroxidation in ulcerated gastric tissues. *Pharmacol. Res.*, 43: 23-30.
- Krasi ski R, Tchorzewski H (2007). Hyaluronan-mediated regulation of inflammation. *Post. Hig. Med. Do w.*, 61: 683-689.
- Kujawa MJ, Pechak DG, Fiazmann MY, Caplan AI (1986). Hyaluronin acid bonded to cell culture surface inhibits the program of myogenesis. *Devel. Biol.*, 113: 10-16.
- Li X, Andersson, TB, Ahlstrom M, Weidolf L (2004). Comparison of inhibitory effects of proton pump inhibiting drugs omeprazole, esomeprazole, lansoprazole, pantoprazole and rabeprazole on human cytochrome P450 activities. *Drug Metab. Dispos.*, 32: 821-827.
- Ligumsky M, Sestieri M, Okon F, Ginsburg I (1995) Antioxidants inhibit ethanol-induced gastric injury in the rat. Role of manganese, glycin and carotene. *Scand. J. Gastroenterol.*, 30: 854-860.
- Laurent TC, Laurent UBG, Fraser JRE (1995). Functions of hyaluronan. *Ann. Rheum. Dis.*, 54: 429-432.
- Lym HS, Suh Y, Park CK (2004). Effects of hyaluronic acid on the polymorphonuclear leukocyte (PMN) release of active oxygen and protection of bovine corneal endothelial cells from activated PMNs. *Korean J. Ophthalmol.*, 18: 23-28.
- Marhuenda E, Martin MJ, Alarcon de la Lastra C (1993). Antilucerogenic activity of aescine in different experimental models. *Phytother. Res.*, 7: 13-16.
- Mesa FL, Aneiros J, Cabrera A, Bravo M, Caballero T, Revellas F (2002). Antiproliferative effect of topic hyaluronic acid gel. Study in gingival biopsies of patients with periodontal disease. *Histol Histopathol.*, 17: 747-753.
- Mersereau AW, Hinchey EJ (1982). Role of gastric mucosal folds in formation of focal ulcer in rats. *Surgery*, 91: 150-155.
- Moseley R, Waddington RJ, Embery G (2002). Hyaluronan and its potential role in periodontal healing. *Dent Update*, 29: 144-148.
- Mutoh H, Hiraishi H, Ota S, Ivey, KJ, Terano A, Sugimoto T (1990). Role of oxygen radicals in ethanol -induced damage to cultured gastric mucosal cells. *Am. J. Physiol.*, 258: G603-G609.
- Nagaya HI, Ohara N, Satoh A (1991). Effects of the enantiomers of lansoprazole (AG-1749) on H<sup>+</sup>/K<sup>+</sup>-ATPase activity in canine gastric microsomes and acid formation in isolated canine parietal cells. *Biochem. Pharmacol.*, 42: 1875-1878.
- Njar VCO, Adesanwo JK, Raji Y (1995). Methyl angolensate: The antiulcer agent of the stem bark of *Entandrophragma angolense*. *Planta Medica*, 61: 91-92.
- Pagnacco A, Vangelisti R, Erra C, Poma A (1997). Double blind clinical trial versus placebo of a new sodium-hyaluronate-based gingival gel. *Translation Int. Therapeut. Curr. News*, 15: 1-7.
- Paiva LAF, Rao VSN, Gramosa NV, Silveira FR (1998). Gastroprotective effect of *Copaifera langsdorffii* oleo-resin on experimental gastric ulcer models in rats. *J. Ethnopharmacol.*, 62: 73-78.
- Pedernera AM, Guardia T, Caleron CG, Rotelli AF, de la Rocha NF, di Genaro S, Pelze LF ( 2006). Antilucerogenic and anti-inflammatory activity of the methanolic extract of *Larrea divaricata* Cav. in rat. *J. Ethnopharmacol.*, 105: 415-420.
- Piper DW, Stiel D (1986). Pathogenesis of chronic peptic ulcer, current thinking and clinical implications. *Med. Progr.*, 2: 7-10.
- Piraza P, Wolinsky L, Nachnani S, Haake S, Pilloni A, Bernhard GW (1999). Bacteriostatic effects of hyaluronic acid. *J. Periodontol.*, 70: 370-374.
- Satoh H, Inatomi N, Nagaya H, Ianda I, Nohara A, Nakamura H (1989). Antisecretory and antiulcer activities of novel proton pump inhibitor AG-1749 in dogs and rats. *J. Pharmacol. Exp. Ther.*, 248: 806-815.
- Schimizzi AL, Massie JB, Murphy M, Perry A, Kim CW, Garfin SR, Akeson WH (2006). High molecular-weight hyaluronan inhibits macrophage proliferation and cytokine release in the early wound of a preclinical postlaminectomy rat model. *Spine J.*, 6: 550-556.
- Shimizu N, Watanabe T, Arakawa T, Fujiwara Y, Higuchi K, Kuroki T (2000). Pentoxifylline accelerates gastric ulcer healing in rats: Roles of tumor necrosis factor alpha and neutrophils during the early phase of ulcer healing. *Digestion.*, 6: 157-164.
- Stern R, Asari AA, Sugahara KN (2006). Hyaluronan fragments: An information-rich system. *Eur. J. Cell. Biol.*, 85: 699-715.

- Suzuki Y, Ishihara M, Ito M (1998). Anti-ulcer effects of antioxidants, quercetin,  $\alpha$ -tocopherol, nifedipine and tetracycline in rats. *Jpn. J. Pharmacol.*, 78: 435-441.
- Suzuki Y, Yamaguchi T (1993). Effects of hyaluronic acid on macrophage phagocytosis and active oxygen release. *Agents Actions*, 38: 32-37.
- Swarnakar S, Ganguly K, Kundu P, Banerjee A, Maity P, Sharma AV. (2005). Curcumin regulates expression and activity of matrix metalloproteinases 9 and 2 during prevention and healing of indomethacin-induced gastric ulcer. *J. Biol. Chem.*, 280: 9409-9415.
- Szabo S, Kusstatscher S, Sakoulas G, Sandor Z, Vincze A, Jadus, M (1995). 'Growth factors: New —endogenous drugll for ulcer healing', *Scand. J. Gastroenterol.*, 210: 15-18.
- Takeuchi K, Nobuhara Y (1985). Inhibition of gastric motor activity by 16, 16-dimethyl-prostaglandin E<sub>2</sub>; a probable explanation of cycloprotection. *Digest. Dis. Sci.*, 30: 1181-1188.
- Takeuchi K, Nishiwakki K, Okabe S (1987). Effect of dopamine on gastric mucosal lesion induced by ethanol in rats—possible involvement of antigastric motor activity mediated with alpha 2 adrenoreceptors. *Digest. Dis. Sci.*, 31: 1100-1107.
- Toole BP, Munaim SI, Welles S, Knudson CB (1989). Hyaluronate-cell interactions and growth-factor regulation of hyaluronate synthesis during limb development. In: *The biology of hyaluronan*. Chichester (UK): Wiley and Sons, pp. 138-149.
- Trivedi NP, Rawal UM (2001). Hepatoprotective and antioxidant property of *Andrographis paniculata* Nees in BHC induced liver damage in mice. *Indian J. Exp. Biol.*, 39: 41-46.
- Tsukimi Y, Nozue C, Okabe S (1996). Effects of teminoprazole, omeprazole and sucralfate on indomethacin-induced delayed healing of kissing gastric ulcers in rats. *J. Gastroenterol. Hepatol.*, 11: 335-340.
- Weigel PH, Fuller GM, Leboeuf R (1986). A model for the role of hyaluronic acid and fibrin in the early events during inflammatory response and wound healing. *J. Theor. Biol.*, 119: 219-234.
- Zhao H, Tanaka T, Mitlitski V, Heeter J, Balazs EA, Darzynkiewicz Z (2008). Protective effect of hyaluronate on oxidative DNA damage in WI-38 and A549 cells. *Int. J. Oncol.*, 32: 1159-1167.
- Zimmerman JJ, Ciesielski W, Lewandoski, J (1997). Neutrophil-mediated phospholipids peroxidation assessed by gas chromatography-mass spectroscopy. *Am. J. Physiol.*, 273: 653-661.