

Case Report

Acute fracture of OS trigonum with cartilaginous articulation

Bekir Yavuz Uçar^{1*}, Demet Uçar², Mehtap Bozkurt², Mehmet Bulut¹ and Ibrahim Azboy¹

¹Dicle University Medical School Department of Orthopaedics and Traumatology, 21280 Diyarbakır, Turkey.

²Diyarbakır Education Research Hospital Clinical Of Physical Medicine and Rehabilitation, Turkey.

Accepted 12 November, 2014

Os trigonum as one of the most common accessory ossicles of foot, may have a fibrocartilaginous articulation with posterior process of talus. This articulation may be misdiagnosed as a fracture of the posterior process of talus. Despite well known chronic injuries of athletes, acute fracture of the os trigonum is rare. Hyperplantarflexion and inversion of the ankle is the mechanism of injury. We report a case of an acute fracture of the os trigonum with a fibrocartilaginous articulation diagnosed with computerized tomography which highlights the importance of considering such injuries in patients with acute posterior ankle pain and 'nut cracker' sign positivity and obtaining advanced imaging modalities in ankle sprains.

Key words: Os trigonum, talus, fracture, ankle sprain, accessory ossicle, foot.

INTRODUCTION

The os trigonum is an accessory ossicle located at the posterolateral aspect of the talus (Mann and Owsley, 1990). Os trigonum appears as a secondary ossification center. It may develop as a separate bone adjacent to the lateral tubercle of the posterior process of talus, having a fibrous, fibrocartilaginous or cartilaginous articulation, or it may fuse becoming a part of the posterior process of talus. Radiological studies reported the prevalence of os trigonum between 2.3 and 23.5% (Coskun et al., 2009; Cilli and Akçaoğlu, 2005).

Chronic repetitive trauma causing os trigonum syndrome is a well known injury especially in athletes participating in sports that require hyperplantarflexion of the foot (Hamilton et al., 1996). On the contrary, acute fracture of os trigonum is extremely rare with a few reported cases in the literature (Mouhsine et al., 2004; Escobedo et al., 2006; Kose et al., 2006).

In this report, we describe a patient who was presented with acute hind foot pain after forceful hyperflexion of the foot. Although initial radiographs did not clearly demonstrated the fracture, careful physical examination, high degree of suspicion and appropriate radiographs and CT scan revealed the diagnosis of fracture of os trigonum.

CASE REPORT

A 21-year-old man presented with ankle pain after ankle sprain while jumping in the football match. He described experiencing hyperplantarflexion and inversion of his left ankle. On physical examination, the ankle was swollen and tender with palpation especially on the posterior aspect of his ankle. Direct radiographs showed a linear lucency in the same plane of os trigonum articulating surface with lateral tubercle of the posterior process (Figure 1).

Computerized tomography scans of the ankle was obtained two days after admission which showed both the fibrocartilaginous articulation of os trigonum and the plane of fracture (Figure 2).

Since the pain was not intense and patient did not prefer cast application, he was kept nonweight bearing for three weeks with crutches and then allowed weightbearing as tolerated. Two months after initial injury, clinically complete recovery was observed together with healing of fracture on follow up radiograph and CT (Figure 3).

RESULTS, DISCUSSION AND CONCLUSION

Acute ankle sprain and residual pain is one of the most

*Corresponding author. E-mail: drbyucar@yahoo.com.



Figure 1. Lateral ankle radiograph shows os trigonum on the right foot and a linear lucency extending anterior to os trigonum with well corticated margins, indicating fibrocartilaginous articulation.

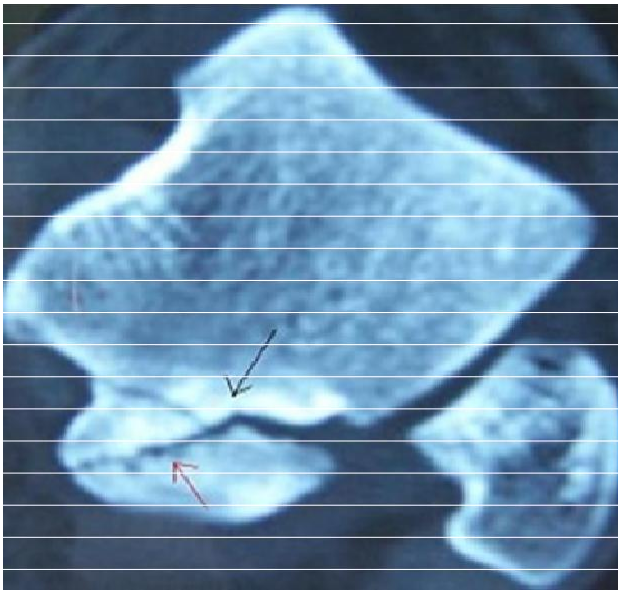


Figure 2. Axial CT scan revealed both fibrocartilaginous articulation with sclerotic margins (black arrow) and acute fracture with no sclerotic margin (red arrow).

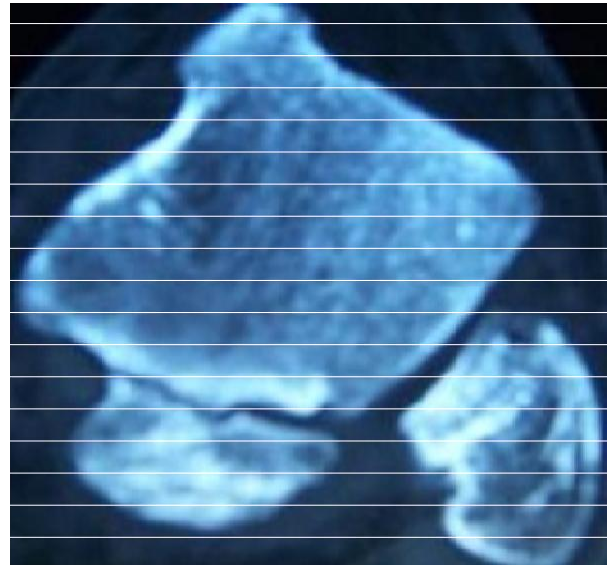


Figure 3. Axial CT scan showing complete bone incorporation of the fracture and plane of articular surface.

common presenting complaints in daily orthopedic practice. Fracture of accessory ossicle is one of the cause of easily neglected associated injuries of ankle sprain. Considering both the high incidence of ankle sprains, high prevalence of os trigonum in the population and the rarity of associated diseases, the presence of os

trigonum on a lateral x-ray following in the acute trauma setting was appeared to be a radiological curiosity for most of the physicians in daily orthopedic practice.

During differential diagnosis of os trigonum fracture from other common injuries; three factors should raise attention. Firstly, is the type of injury, which is most commonly hyperplantar flexion of the foot rather than simple inversion injury.

Because, forced plantarflexion of the foot causing impingement of the os trigonum between posterior malleolus of tibia and tuber calcaneus is the most common mechanism of injury. Secondly, pain in the posterior aspect of the ankle rather than anterolateral tenderness and lastly, pain during forced plantarflexion of the ankle during physical examination is called positive 'nut cracker' sign (Schubert and Adler, 2001). Our patient had a posterior ankle pain after a hyperflexion trauma and also had positive 'nut cracker' sign.

Direct roentgenograms may indicate fracture only seldomly, in most of the cases direct x-rays found to be positive retrospectively. Plain x-ray of our patient showed a radiolucent line with sclerotic ends on both sides was thought to be the plane of fibrocartilaginous articular surface of os trigonum. However, localized pain in that region and positivity of 'nut cracker' sign had necessitated further diagnostic work up. Computerized tomography of the suspected region usually was the first radiologic examination demonstrating the fracture of os trigonum which was also true in our patient. CT scan showed both the articular surface of os trigonum which was apparent on direct x-rays and line of fracture. Magnetic resonance imaging can be also helpful in differentiating other common ligamentous and cartilaginous injuries.

Conservative treatment including rest and short period of cast application (3 to 6 weeks) is usually successful although nonunion has been reported (Escobedo et al., 2006). In the case of asymptomatic nonunion no further treatment is recommended (Chao, 2004). Symptomatic os trigonum mass can be a surgical indication whether with or without union (Hamilton et al., 1996).

In our case, non weight bearing for three weeks and following weightbearing as tolerated resulted in early control of edema and pain. Patient was asymptomatic

with bone union two months after initial injury. Ankle sprains with hyperplantarflexion injuries with posterior ankle pain and positive 'nut cracker sign' should raise the suspicion of fracture of os trigonum. Misdiagnosis of such injuries may cause inadequate management including immediate weightbearing and prolonged symptoms. Short immobilization and controlled weightbearing result in satisfactory results.

REFERENCES

- Mann RW, Owsley DW (1990). Os trigonum. Variation of a common accessory ossicle of the talus. *J. Am. Pediatr. Med. Assoc.*, 80(10): 536-569.
- Coskun N, Yuksel M, Cevener M, Arican RY, Ozdemir H, Bircan O, Sindel T, Ilgi S, Sindel M (2009). Incidence of accessory ossicles and sesamoid bones in the feet: a radiographic study of the Turkish subjects. *Surg. Radiol. Anat.*, 31(1): 19-24.
- Cilli F, Akçaoğlu M (2005). The incidence of accessory bones of the foot and their clinical significance. *Acta. Orthop. Traumatol. Turc.*, 39(3): 243-246.
- Hamilton WG, Geppert MJ, Thompson FM (1996). Pain in the posterior aspect of the ankle in dancers. Differential diagnosis and operative treatment. *J. Bone Joint Surg. Am.*, 78(10): 1491-500.
- Mouhsine E, Djahangiri A, Garofalo R (2004). Fracture of the non fused os trigonum, a rare cause of hindfoot pain. A case report and review of the literature. *Chir. Organ. Mov.*, 89(2): 171-175.
- Escobedo EM, MacDonald TL, Hunter JC (2006). Acute fracture of the os trigonum. *Emerg. Radiol.*, 13(3): 139-141.
- Kose O, Okan AN, Durakbasa MO, Emrem K, Islam NC (2006). Fracture of the os trigonum: A case report. *J. Orthop. Surg. (Hong Kong)*, 14(3): 354-356.
- Schubert JM, Adler DC (2001). Talar fractures. *McGlamry's comprehensive textbook of foot and ankle surgery*. Lippincott Williams and Wilkins, 3rd ed. Philadelphia, 1: 1871-1874.
- Chao W (2004). Os trigonum. *Foot Ankle Clin.*, 9(4): 787-796.