

Full Length Research Paper

Effects of *Hypericum perforatum* (St. John's wort) extract on renal function after unilateral ureteral obstruction in rat

Mehrdad Neshat^{1*}, Yadollah Azarmi², Ziaii Seyed Mehdi¹, Yousef Doustar³ and Ghafour Mousavi⁴

¹Department of Clinical Science, Faculty of Veterinary Medicine, Tabriz Branch, Islamic Azad University, Tabriz - Iran.

²Department of Pharmacology, Faculty of Pharmacy, Tabriz University of Medical Sciences, Iran.

³Department of Pathology, Faculty of Veterinary Medicine, Tabriz Branch, Islamic Azad University, Tabriz - Iran.

⁴Department of Clinical Science, Faculty of Veterinary Medicine, Tabriz Branch, Islamic Azad University, Tabriz - Iran.

Accepted 18 April, 2016

Obstructive nephropathy induced by urine reflux due to uroliths, prostatic hypertrophy and other disorders will result in renal interstitial fibrosis and inflammation. Because of *Hypericum perforatum* (HP) anti-oxidant and anti-inflammatory properties, the clinical usage of this drug in renal function has been studied. We divided 30 Sprague- Dawley rats randomly into 5 groups: sham group (Sham), untreated unilateral ureteral obstruction (UUO) group, vitamin E treated (50 IU/kg) UUO group, HP 30 and 60 treated (30 and 60 mg/kg) UUO groups. All of the chemicals were administrated 7 days before and after operation. At 7 days after UUO, blood samples were collected and left kidney were dissected and Haematoxylin and Eosin (HE) and Masson staining were used to study the dynamic histological changes. Low dose of HP similar to vitamin E alleviated the renal interstitial fibrosis, tubular cell degeneration, inflammatory cell infiltration and glomerular damage ($p < 0.01$) but high dose of HP increased injuries ($p < 0.05$). We provide for the first time evidence that HP extract in obstructed kidney has different effects, such that in low dose it can be affected as a renoprotective agent, but in high dose, it can be affected as an inflammation triggering substance. The demonstration of exact mechanism (s) of opposite effect of HP extracts needs more cellular and molecular investigations.

Key words: *Hypericum perforatum*, renal glomerular damage, renal tubulointerstitial damage, unilateral ureteral obstruction.

INTRODUCTION

Obstructive nephropathy due to congenital or acquired urinary tract obstruction may be induced by urolithiasis is the major cause of chronic renal failure (CRF). Urinary tract obstruction leads to progressive and permanent loss of renal function characterized by a progressive epithelial-to-mesenchymal cell transition (EMT)-driven interstitial fibrosis (Cheng et al., 2010). A variety of factors with complex molecular interactions has been proposed as possible causes leading to these histologic

changes. Ureteral obstruction is characterized by an inflammatory state in the kidney, that is promoted by cytokines and growth factors produced by damaged tubular cells and infiltrated macrophages. This inflammatory state contributes to tubular atrophy and interstitial fibrosis (Grande et al., 2010; Klahr and Morrissey, 2002). Accumulation of leukocytes, especially macrophages and lymphocytes, in the renal interstitium is strongly associated to the progression of renal injury (Chevalier et al., 2009; Grande et al., 2010). *Hypericum perforatum* (St. John's Wort) has been used in traditional medicine since time immemorial and it has its position also in the contemporary list of medicinal plants of pharmaceutical importance. *Hypericum perforatum* contains numerous

*Corresponding author. E-mail: neshatpetvet@yahoo.com. Tel: 00989143155831.

compounds such as flavonol glycosides (rutin, hyperoside, isoquercitrin, quercitrin, miqueliani), biflavonoids (I3,I18-biapigenin and amentoflavone) and naphthodianthrones hypericin and pseudohypericin (Butterweck and Schmidt, 2007; Lawvere and Mahoney, 2004). Hypericin and pseudohypericin are polycyclic-phenolic structurally related compounds found in *Hypericum perforatum* are potent antioxidants (Benedí et al., 2004; Lu et al., 2004; Medina et al., 2006; Laggner et al., 2007). Also hyperforin one of the major compound of HP can suppress Nf-kappa B activation (Kraus et al., 2010; Menegazzi et al., 2006). Oxidative stress has been implicated in the pathogenesis of various forms of renal injury. Oxidative stress is also a major activator of the NF-B and thus, an inductor of the inflammatory state. There are several evidences showing that increased oxidative stress is involved in renal inflammatory damage after UJO (Grande et al., 2010). These finding indicate that the derivatives found in *Hypericum perforatum* have possible renoprotective effects. Therefore, it is hypothesized that *Hypericum perforatum* extract prevents renal injury in a model of unilateral ureteral obstruction, and this hypothesis was tested in this study.

MATERIALS AND METHODS

Animals

Healthy male Sprague Dawley rats, weighing between 300±10 g, were obtained from the Pasteur Institute of Iran. They were housed in polyethylene cages in groups of four rats per cage and were kept in a room maintained at a temperature of 25 ± 2°C with a natural light: dark cycle. This study was reviewed and approved by the Ethics Committee of Tabriz University of Medical Sciences.

Chemicals

Ketamine hydrochloride, xylazin and vitamine E (VitE), were obtained from Alfasan, Holland and Osveh, Iran respectively.

Extract preparation

Powdered leaves of HP were extracted three times with 1 L of 70% methanol (MeOH)/H₂O while being macerated at room temperature for 24 h each time. The hydroalcoholic extracts were combined and concentrated in vacuo to yield dried extract and it was defined by the producer as containing 0.28% hypericin. This hydroalcoholic extract was kept in refrigerator for all experiments.

Experimental protocols

All rats except for the sham-operated rats underwent UJO. Under ketamin and xylazin (60+2 mg/kg intraperitoneally) anesthesia, a midline incision of the abdomen was made, and the left ureter was ligated with 4 to 0 silk at three points and cut between the distal ligatures. The sham-operated rats underwent a similar procedure, but without ureteral ligation. To examine the effect of HP extract and Vitamine E, the rats were divided into five groups as follows: group 1, sham operated rats; group 2 unilateral ureteral ligated rats

(n=6); group 3 unilateral ureteral ligated rats that received Vitamine E 50 IU/kg/day by ip 7 days before UJO and 7 days after UJO (n=6) group 4, unilateral ureteral ligated rats that received HP extract 30 mg/kg/day by gavage 7 days before UJO and 7 days after UJO (n=6); group 5, unilateral ureteral ligated rats that received HP extract 60 mg/kg/day by gavage 7 days before UJO and 7 days after UJO (n=6). All rats received the drug solution or vehicle daily by gavage (4 ml/kg). The doses of HP extract were based on the finding that HP extract at a dose of 30 mg/kg by gavage successfully attenuates the development of carrageenan-induced lung injury (Menegazzi et al., 2006). At 7 days after UJO, the rats were anesthetized with ketamin and xylazin (60+2 mg/kg intraperitoneally), blood samples were collected from tail vein and centrifuged for 10 min at 5,000 rpm. The obtained clear sera were stored at -20°C for subsequent measurement of blood urea nitrogen and serum creatinine levels using colorimetric assay kits according to the manufacturer's instructions (Pars Azmun, Iran).

Then left kidney were dissected and were stored in buffered formalin (10%) for staining with H and E and Masson's Trichrome. At least five slides from each kidney were stained for histological assessment that including Bowman's capsular extension, renal tubular atrophy, tubular cell necrosis, deposition of connective matrix in glomerular tuft, deposition of connective matrix in renal interstitial space, glomerular tuft atrophy, renal tubular cell degeneration, inflammatory reaction in renal interstitial space and production of Hyaline cast on tubules. Inflammatory cells infiltration and tubulointerstitial changes were graded according to semiquantative system based on lesion histopathology on scale of 0-4, where 0 represented normal kidney; +1, mild (lesions involving less than 25% of the area) injury; +2, moderate (lesions affecting 25 to 50%) injury; +3, severe injury (lesions involving more than 50%); +4, high severe injury (lesions almost involving the entire area). The glomerular score for individual glomeruli was: grade 0, normal glomerulus; grade 1, mild mesangial expansion/thickening of the basement membrane and/or irregular lumina of capillaries; grade 2, mild/moderate segmental hyalinosis/sclerosis involving less than 50% of the glomerular tuft; grade 3, diffuse glomerular hyalinosis/sclerosis involving more than 50% of the tuft; grade 4, diffuse glomerulosclerosis with total tuft obliteration and collapse. The glomerular score of each animal was derived as the mean of 100 glomeruli, the resulting index was expressed as a mean of all scores obtained. All sections were scored by a single pathologist who was blinded to group.

Statistical analysis

The data are presented as the mean±standard error. All data were analyzed using analysis of variance, and individual comparisons were made using Tukey-Kramer Multiple Comparisons Test. Statistical significance was defined as P <0.05.

RESULTS

Effect of HP extract on blood urea nitrogen and serum creatinine levels

Unilateral ureteral obstruction resulted in significant rises in blood urea nitrogen and serum creatinine levels as compared to the sham values. Vitamine E (50 IU/kg) and HP extract (30 mg/kg) treatment groups significantly reduced blood urea nitrogen and serum creatinine (Table 1). But in HP extract (60 mg/kg) group, blood urea nitrogen and serum creatinine levels were not changed

Table 1. Effects of *Hypericum perforatum* extract treatment on blood urea nitrogen (BUN) and serum creatinine (SCr) levels in unilateral ureteral obstructed rat.

Group	n	BUN(mg/dl)	SCr (mg/dl)
Sham	6	12.11±0.84	1.20 ±0.083
UUO	6	54.34±2.6 [#]	2.10±0.15 [#]
UUO+VitE	6	17.21±0.6 [*]	1.43±0.13 [*]
UUO+HP30	6	28.78±1.76	1.81±0.14
UUO+HP60	6	49.53±2.4	2.40±0.16

VitE: vitamin E 50 IU/kg; HP30, *Hypericum perforatum* 30 mg/kg; HP60, *Hypericum perforatum* 60 mg/kg; ^{*} Significant difference versus UUO group, p<0.05; [#] Significant difference versus sham group, p<0.05.

compared to the UUO values.

Effect of HP extract on tubulointerstitial histopathological changes

In the sham group, which received vehicle the morphology of tubulointerstitial area remained normal under light microscopy. In UUO group, which received vehicle, tubulointerstitial changes including renal tubular atrophy, deposition of connective matrix in renal interstitial space, renal tubular cell degeneration, inflammatory reaction in renal interstitial space and production of hyaline cast on tubules significantly increased in comparison with sham group (p<0.001). In UUO group treatment with Vitamin E (50 IU/kg) this increase significantly attenuated (p<0.001). In *Hypericum perforatum* received groups deposition of connective matrix in renal interstitial space and production of hyaline cast on tubules significantly decreased (HP30 p< 0.001, HP60 p<0.05). Also in UUO rats under treatment with low dose HP(30 mg/kg), renal tubular cell degeneration, inflammatory reaction in renal interstitial space and tubular cell necrosis significantly decreased (p<0.01) but renal tubular atrophy increased (p<0.05). high dose HP (60 mg/kg), induced tubular cell necrosis (p<0.05), attenuate inflammatory reaction in renal interstitial space (p<0.05) but renal tubular cell degeneration was unchanged (Table 2).

Effect of HP extract on glomerular histopathological changes

In the sham group the morphology of glomerules remained normal under light microscopy. In UUO group Bowman's capsular extension, deposition of connective matrix in glomerular tuft and glomerular tuft atrophy was significantly increased in comparison with sham group (p<0.001, Figures 1 and 2). Vitamin E administration in UUO group improved deposition of connective matrix in

glomerular tuft and glomerular tuft atrophy (p<0.001). In low dose HP (30 mg/kg) deposition of connective matrix in glomerular tuft (p<0.001) and glomerular tuft atrophy (p<0.01) were significantly decreased. In contrast, high dose HP (60 mg/kg) augmented glomerulosclerosis and glomerular tuft atrophy (p<0.05, Figure 1 and 2).

DISCUSSION

In present study we demonstrate that tubulointerstitial and glomerular histopathological changes were diminished in low dose of HP similar to Vitamin E in groups have been tolerated UUO, but administrating of high dose of HP enhanced renal damage. Rat unilateral ureteral obstruction is a classical model of human obstructive nephropathy that induced by several factors. Absence of extra renal clinical manifestations of UUO such as hypertension, hyperlipidemia, proteinuria and because of nonimmunological tubulointerstitial and glomerular histopathological events that often processed by cellular - molecular and oxidative stress pathways, in this kind of renal injury, elaborating of compounds with antioxidative properties will be considerable in attenuation of the abovementioned damages.

The bioactive constituents of HP extracts are complex and include many different classes of chemicals (Hammer et al., 2007). Some classes of constituents present within HP are potent antioxidants (Benedi et al., 2004; Lu et al., 2004; Medina et al., 2006). For example hyperforin and hypericin the major compounds of HP can suppress Nf-kappa B activation (Bork et al., 1999; Menegazzi et al., 2006).

Oxidative stress has been implicated in the pathogenesis of various forms of renal injury. Oxidative stress is also a major activator of the NF- B and thus, an inductor of the inflammatory state. There are several evidences showing that increased oxidative stress is involved in renal inflammatory damage after UUO (Grande et al., 2010). This work showed that HP with low dose can protect renal damage induced by UUO may be by attenuation of oxidative stress.

The other considerable finding of this study was increasing of renal damage due to high dose of HP administration versus to low dose. In interpretation of this paradoxical effect of HP it seems that antioxidative effect of potent agent in extract may be affected by hazardous chemicals. Although individual constituents have been shown to provide bioactivity alone, the interaction among constituents may account for diverse bioactivities of the extract.

In conclusion, we provide for the first time evidence that HP extract in obstructed kidney has different effects. So that in low dose it can be affect as a renoprotective agent similar to Vitamine E but in high dose can be affect as inflammation triggering substance. The demonstration of exact mechanism (s) of opposite effect of HP extracts need to be more cellular and molecular investigations.

Table 2. Effects of *H. perforatum* extract on tubulointerstitial changes in unilateral ureteral obstructed rat.

Group	TI change	Tubular atrophy	Tubular cell necrosis	Deposition of connective matrix in interstitial space	Tubular cell degeneration	Inflammatory reaction in interstitial space	Hyaline cast on tubules
Sham		0.1±0.01	0.17 ±.17	0.1±0.01	0.3±0.21	0.17±0.17	0.17±0.17
UUO		2.83±0.17 [#]	3.67±0.21 [#]	3.5±0.22 [#]	3.83±0.17 [#]	3.83±0.17 [#]	3.83±0.17 [#]
UUO + Vit. E		1.5±0.22 ^{***}	1.67±0.21 ^{**}	1.17±0.17 ^{***}	1.67±0.21 ^{**}	1.17±0.17 ^{**}	1.17±0.17 ^{***}
UUO+HP30		3.5±0.22 ^{***}	2.67±0.21 ^{**}	1.67±0.21 ^{***}	2.67±0.21 ^{**}	2.67±0.21 ^{**}	1.67±0.21 ^{***}
UUO+HP60		3.5±0.22 ^{***}	3.88±0.17 ^{**}	3.17±0.17 ^{***}	3.83±0.17 ^{**}	3.67±0.21 ^{**}	3.17±0.17 ^{***}

TI, Tubulointerstitial; UUO, unilateral ureteral obstruction; Vit. E: vitamin E 50 IU/kg; HP30, *Hypericum perforatum* 30 mg/kg; HP60, *Hypericum perforatum* 60 mg/kg; ^{*} Significant difference versus UUO group, p<0.05; ^{**} Significant difference versus UUO group, p<0.01; ^{***} Significant difference versus UUO group, p<0.001; [#] Significant difference versus sham group, p<0.001.

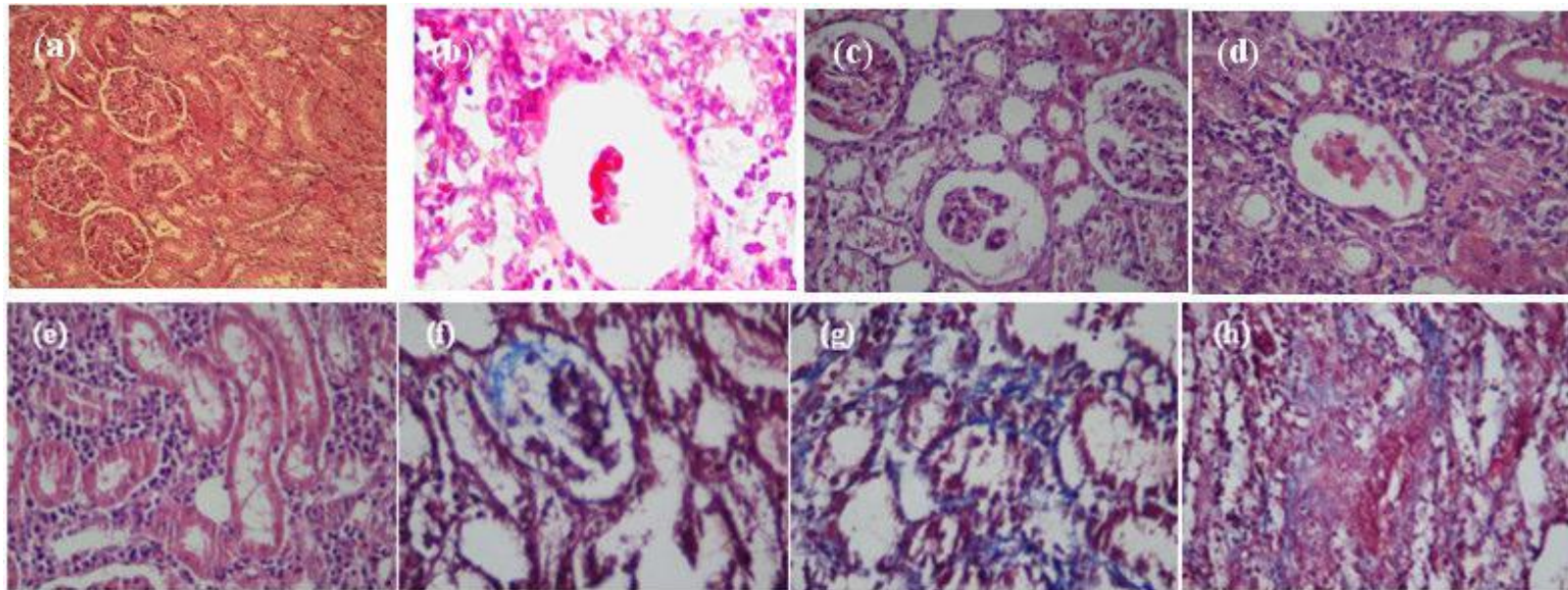


Figure 1. Sections of the rat kidneys stained with hematoxylin and eosin and Masson of different groups. (a-e) Representative photographs of histologic changes visualized by hematoxylin and eosin staining; (f-h) Representative photographs of histologic changes visualized by Masson staining. (a) Sham-operated control rats; (b) Untreated UUO control rats; (c) and (f) Vitamin E-treated rats; (d) and (g) *Hypericum perforatum* (30 mg/kg) -treated rats; (e) and (h) *Hypericum perforatum* (60 mg/kg). Changes in renal tissue injury including inflammatory reaction in interstitial space, tubular cell degeneration, deposition of connective matrix in interstitial and glomerular space and Glomerular atrophy were shown in this section.

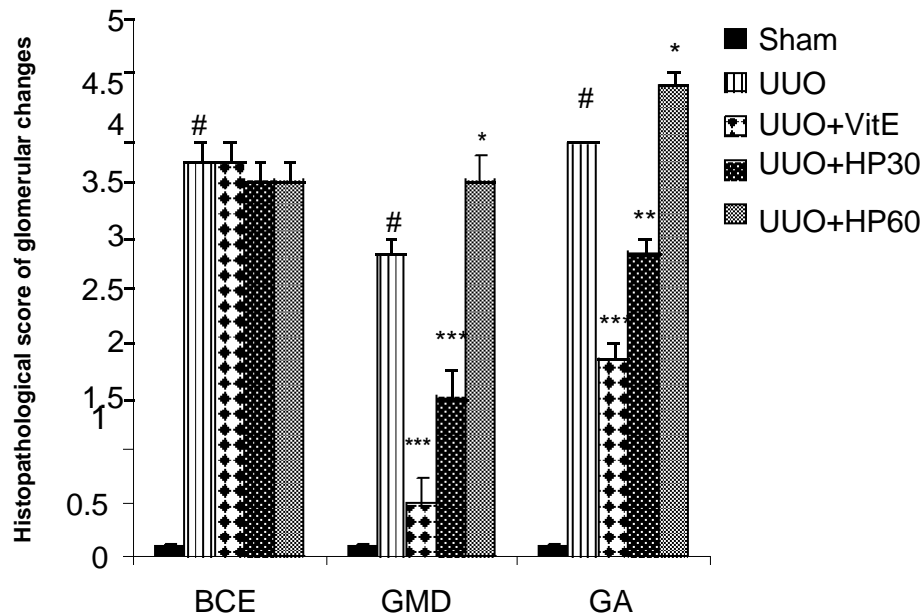


Figure 2. Effects of *Hypericum perforatum* extract on glomerular changes in unilateral ureteral obstructed rat. BCE, Bowman's capsular extension; GMD, Glomerular matrix deposition; GA, Glomerular atrophy; UUO, unilateral ureteral obstruction; VitE: vitamin E 50 IU/kg; HP30, *Hypericum perforatum* 30 mg/kg; HP60, *Hypericum perforatum* 60 mg/kg; # Significant difference versus UUO group, $p < 0.05$; * Significant difference versus UUO group, $p < 0.01$; ** Significant difference versus UUO group, $p < 0.001$; # significant difference versus sham group, $p < 0.001$.

REFERENCES

- Benedí J, Arroyo R, Romero C, Martín-Aragón S, Villar AM (2004). Antioxidant properties and protective effects of a standardized extract of *Hypericum perforatum* on hydrogen peroxide-induced oxidative damage in PC12 cells. *Life Sci. J.*, 75(10): 1263-76.
- Bork PM, Bacher S, Schmitz ML, Kaspers U, Heinrich M (1999). Hypericin as a non-antioxidant inhibitor of NF-kappa B. *Plant. Medica.*, 65(4): 297-300.
- Butterweck V, Schmidt M (2007). St. John's wort: role of active compounds for its mechanism of action and efficacy. *Wien. Med. Wochenschr.*, 157: 356-61
- Cheng J, Truong LD, Wu X, Kuhl D, Lang F, Du J (2010). Serum and glucocorticoid regulated kinase 1 is upregulated following unilateral ureteral obstruction causing epithelial-mesenchymal transition. *Kidney Int. J.*, 78(7): 668-78.
- Chevalier RL, Forbes MS, Thornhill BA (2009). Ureteral obstruction as a model of renal interstitial fibrosis and obstructive nephropathy. *Kidney. Int. J.*, 75(11): 1145-52.
- Grande M, Pérez-Barriocanal F, López-Novoa JM (2010). Role of inflammation in túbulo-interstitial damage associated to obstructive nephropathy. *J. Inflammation*, 7: 19-32.
- Hammer KD, Hillwig ML, Solco AK, Dixon PM, Delate K, Murphy PA, Wurtele ES, Birt DF (2007). Inhibition of prostaglandin E(2) production by anti-inflammatory *Hypericum perforatum* extracts and constituents in RAW264.7 Mouse Macrophage Cells. *J. Agric. Food Chem.*, 55(18): 7323-31.
- Klahr S, Morrissey J (2002). Obstructive nephropathy and renal fibrosis. *Am. J. Physiol. Renal. Physiol.*, 283(5): 861-75.
- Kraus B, Wolff H, Elstner EF, Heilmann J (2010). Hyperforin is a modulator of inducible nitric oxide synthase and phagocytosis in microglia and macrophages. *Naunyn-Schmiedeberg's. Arch. Pharmacol.*, 381(6): 541-53.
- Laggner H, Schreier S, Hermann M, Exner M, Mühl A, Gmeiner BM, Kapiotis S (2007). The main components of St John's Wort inhibit low-density lipoprotein atherogenic modification: a beneficial "side effect" of an OTC antidepressant drug? *Free. Radical. Res.*, 41(2): 234-41.
- Lawvere S, Mahoney MC (2005). St John's wort. *Am. Family. Phys.*, 72(11): 2249-54.
- Lu YH, Du CB, Liu JW, Hong W, Wei DZ (2004). Neuroprotective effects of *Hypericum perforatum* on trauma induced by hydrogen peroxide in PC12 cells. *Am. J. Chinese Med.*, 32(3): 397-405.
- Medina MA, Martínez-Poveda B, Amores -Sánchez MI, Quesada AR (2006). Hyperforin: more than an antidepressant bioactive compound? *Life Sci. J.*, 79(2): 105-11.
- Menegazzi M, Di Paola R, Mazzon E, Muià C, Genovese T, Crisafulli C, Suzuki H, Cuzzocrea S (2006). *Hypericum perforatum* attenuates the development of carrageenan-induced lung injury in mice. *Free Radical Biol. Med. J.*, 40(5): 740-53.