

Full Length Research Paper

Hepatomodulatory role of *Enicostemma littorale* Blume against oxidative stress induced liver injury in rats

R.S. Gupta* and Dharmendra Singh

Reproductive Physiology Section, Centre for Advanced Studies, Department of Zoology, University of Rajasthan, Jaipur – 302 004, India

Accepted 16 December, 2012

The hepatomodulatory response of ethanol extract of *Enicostemma littorale* Blume was examined in contrast to oxidative stress-induced liver injury by carbon tetrachloride (CCl₄) in albino wistar male rats. The rats received the extract, orally at the doses of 125, 250 and 500 mg/kg b wt/day for 21 consecutive days and CCl₄, at the dose of 0.2 ml/kg b wt/twice a week, i.p with olive oil, in the ratio 1:1 treatment. The rats subjected only CCl₄ with olive oil, showed remarkable oxidative stress-induced liver injury. Supplementation of *E. littorale* extract significantly ($P \leq 0.001$) increased the hepatic reduced glutathione (GSH), glutathione- s-transferase (GST), glutathione peroxidase (GPx), superoxide dismutase (SOD), catalase (CAT) and vitamin-C (vit. C) in the liver, with a dose-dependent reduction of the thiobarbituric acid reactant substances (TBARS) as evidenced by reduced hepatic lipid peroxidation (LPO) levels, compared with the control animals. The hepatic total cholesterol and triglycerides level were also significantly decreased in the groups receiving *E. littorale* extract, in comparison to controls. Further, the hepatic marker levels-AST, ALT (aspartate and alanine transaminases), ALP (alkaline phosphatase), ACP (acid phosphatase), γ -GTP (gamma glutamyl transpeptidase), LDH (lactate dehydrogenase), SDH (sorbitol dehydrogenase), Total bilirubin, total protein and albumin in serum were also restored to normal level dose-dependently after the supplementation of *E. littorale* extract in comparison to respective controls. These biochemical observations were strongly supported by a comparative histoarchitectural examination of liver sections from treated groups, further corroborated the hepatomodulatory role of *E. littorale* extract. Silymarin was used as standard drug for comparison with the *E. littorale* extract. In conclusion, these results suggest the hepatomodulation by *E. littorale* Blume against oxidative stress mediated through interference with free radical generation and reduction in fat metabolism.

Key words: Carbon tetrachloride, *E. littorale*; Free radicals, Hepatomodulation, Oxidative stress

INTRODUCTION

Liver of mammals has been reported as a highly toxicity sensitive organ. Hepatic injury can be life threatening when the entirely or most of the liver is exposed with any hepatotoxicant including CCl₄, which is required metabolic activation, particularly by the liver cytochrome P-450 enzymes, to form reactive, toxic metabolites, which in turn cause liver injury in experimental animals and hum-

humans (Gonzalez, 1988).

CCl₄, a well known model compound for producing chemical hepatic injury because it has been administered to humans in vehicles ranging from shampoo to a drug against hook worm. It was even used as an anesthetic and as an analgesic. CCl₄ was also used in fire extinguishers, being useful for fighting fires near electrical equipment because it does not conduct electricity. Because of its qualities as a solvent, it has been used in industry as cleaning agent, including in the dry cleaning of clothing. CCl₄ still has a number of industrial applications and, despite restrictions on its use, its production continues to increase. Although CCl₄ has largely been restricted to

*Corresponding author. E-mail: gupta_rs@hotmail.com. Tel: +91-141-2711228.

industrial and laboratory uses, instances of CCl₄ toxicity still occur. Most cases have been resulted from industrial exposure, indiscreet domestic use, or accidental ingestion (Williams & Raymond, 1990).

In a serious liver injury through oxidative stress, currently available drugs have little effect and, to create a demand to develop new drugs. Herbs have attracted a great deal of interest as physiologically functional foods and as a source for the development of drugs because herbal constituents may have stimulating or regenerating effect on hepatocytes and restored the activities of hepatic system through their anti-hepatotoxic, antioxidant and anti-hyperlipidemic activities (Lee et al., 2004).

Silybum marianum has been commonly standardized for 70% to 80% silymarin content. A hepatology clinic patient survey found that 31% were using over-the-counter "alternative agents" for the therapy for their liver diseases, the most common being milk thistle (Silymarin) (Flora et al., 1998). In 2001, milk thistle ranked # 12 of the 20 top selling herbs in the mainstream U.S. market (Blumenthal, 2002). Therefore, familiarity with this herb, its constituents, current usage and potential drug interactions is increasingly important for health care provides as growing numbers of those with liver conditions elect to use this supplement (Karen and Kris, 2005).

Enicostemma littorale Blume (Gentianaceae), commonly known as "chhota chiraita" is an indigenous glabrous perennial rainy season herb, growing on moist, damp and shady ridges and slopes of the borders of cultivated fields, found throughout India, bitter in taste and traditionally used in the treatment of malaria, diabetes, rheumatism, hypoglycemia, dropsy, hernia, swellings, itches, filariasis and insect poisoning (Anonymous, 2001). Animal experiments have reported its hypoglycemic activity (Vijayvargia et al., 2000), antidiabetic activity (Murali et al., 2002), though hepatoprotective activity of *E. littorale* is reported (Senthilkumar et al., 2005), the antioxidant properties of *E. littorale* against hepatocellular damage needs to be substantiated because the hepatoprotective activity through antioxidant potential of *E. littorale* are not well established. Preliminary phytochemical studies have revealed the presence of flavonoids, alkaloids and glycosides.

Hence, the present study has been undertaken to investigate the modulatory effects of *E. littorale* extract on oxidative response of the liver against oxidative stress - induced liver injury by CCl₄ in rats.

MATERIALS AND METHODS

Laboratory animals

For the purpose of this study, colony bred, adult, male albino rats, wistar strain with a approximate weight of 170 g each were used. The animals were kept, in polypropylene cages under controlled conditions of temperature (25 ± 3°C), light (14L: 10D) and humidity. The feed consisted of a standard diet marketed by Lipton India, Ltd. Feed and water were available *ad libitum* throughout the period of

the study.

Plant material and extraction

E. littorale, collected from Banswara district in the month of July 2005. The plant was identified and authenticated from the Deptt. of Botany, University of Rajasthan, Jaipur (Specimen No. RUBL – 19815). The whole plants were shade dried and pulverized. The powder was treated with petroleum ether for defatting as well as to remove chlorophyll. The powder was packed into a soxhlet apparatus and subjected to hot continuous percolation using ethanol (95% v/v) as solvent. The extract was concentrated under vacuum and dried in a vacuum desiccator (yield 7.3% w/w) and stored at 4°C until further use. For experimentation, the extract was dissolved in distilled water just before oral administration.

Silymarin was obtained from German Remedies Ltd., Mumbai for using as a standard drug for experimentation.

Treatment Protocol

After acclimatization, the rats were divided into following groups, each group consisting of six animals:

Group I : Untreated rats were kept on normal diet and served as control.

Group II: Rats were intoxicated with CCl₄ (0.2 ml/kg.b.wt./twice a week, ip. with olive oil, 1:1) for 21 days.

Group III: Rats received 125 mg/kg.b.wt./day, PO. with olive oil of silymarin and CCl₄ as group II, for 21 days.

Group IV: Rats received 125 mg/kg.b.wt./day, PO. with olive oil of *E. littorale* extract and CCl₄ as group II, for 21 days.

Group V: Rats received 250 mg/kg.b.wt./day, PO. with olive oil of *E. littorale* extract and CCl₄ as group II, for 21 days.

Group VI: Rats received 500 mg/kg.b.wt./day, PO. with olive oil of *E. littorale* extract and CCl₄ as group II, for 21 days.

On day 22nd, all experimental rats were sacrificed under ether anesthesia and blood samples were collected by cardiac puncture in sterilized vials. Serum was separated and stored at -20°C until assayed. The entire liver was perfused immediately with cold physiological saline and thereafter carefully removed, trimmed free of extraneous tissues. After that, a part of it was fixed in Bouin's fixative and paraffin sections were prepared, stained with haematoxylin and eosin for histoarchitectural examinations. The remaining part was frozen for biochemical analysis.

Analysis and Processing of the Samples

In serum samples, the biochemical analysis of enzymes viz. AST, ALT, ALP, ACP, γ-GTP, LDH, SDH and total bilirubin, total proteins, albumin levels were performed using kit methods. AST (Batch No. 61105), ALT (Batch No. 60865) and γ-GTP (Batch No. 34004) kits were purchased from Accurex Biomedical Pvt. Ltd.; Mumbai, India. LDH (LOT. No. 6854), SDH (LOT No. 6810), ALP (LOT. No. 7093), ACP (LOT. No. 6666), Total bilirubin (LOT. No. 6801), Total protein (LOT. No. 6808) and albumin (LOT. No. 6988) kits were purchased from Span Diagnostics Ltd., Surat, India, respectively.

In tissue samples, the quantitative estimation of total cholesterol (Zlatkis et al., 1953), triglycerides (Gottfried and Rosenberg, 1973), ascorbic acid (Roe and Kuether, 1943), lipid peroxidation (TBARS) (Ohkawa et al., 1979), reduced glutathione (Moron et al., 1979), glutathione-s-transferase (Habig et al., 1974), glutathione peroxidase (Paglia and Valentine, 1967), superoxide dismutase (Marklund and Marklund, 1974) and Catalase (Aebi, 1984) were performed in liver homogenate, respectively.

The hepatomodulation (H), expressed as percentage (%), was calculated using the following equation:

$$H(\%) = \frac{T_1 - T_2}{T_1 - T_3} \times 100$$

Where, T₁ is the mean value of only oxidative stressed animals; T₂ is the mean value of oxidative stressed plus extract and silymarin treated animals and T₃ is the mean value of normal control animals.

Statistical process

The results obtained in the present study were expressed as the mean ± SEM for each parameter and statistically processed by applying student 't' test.

RESULTS

The findings of present investigation indicate the ethanolic extract of *E. littorale*, modulate the liver against oxidative stress in a dose dependent manner without any adverse effect on the animals at the dose levels (125, 250 and 500 mg/kg body weight/day for 21 days, respectively). CCl₄ was used as a oxidative stress agent which was induced-severe liver injury in experimental animals.

Table 1 shows oxidative stress by CCl₄ caused significant (P ≤ 0.001) alterations in hepatic antioxidant defense system like GSH, GST, GPx, SOD, CAT, Vit. C and LPO contents in comparison to the normal controls. Concomitant significant (P ≤ 0.001) elevations of hepatic-total cholesterol and triglycerides were also observed after oxidative stress. Concurrent administration of CCl₄ and *E. littorale* extract at the doses of 125, 250 and 500 mg/kg b wt/day to rats, remarkably antagonised the alteration in antioxidant defense system like GSH 43.08% (P ≤ 0.001), 76.59% (P ≤ 0.001) & 88.83% (P ≤ 0.001); GST 29.17% (P ≤ 0.01), 57.92% (P ≤ 0.001) & 78.75% (P ≤ 0.001); GPx 21.36% (P ≤ 0.05), 50.94% (P ≤ 0.001) & 79.81% (P ≤ 0.001); SOD 16.55% (P ≤ 0.05), 54.19% (P ≤ 0.001) & 81.86% (P ≤ 0.001); CAT 34.09% (P ≤ 0.05), 58.16% (P ≤ 0.01) & 72.59% (P ≤ 0.001); Vit.C 37.63% (P ≤ 0.001), 53.61% (P ≤ 0.01) & 60.82% (P ≤ 0.001); and LPO 42.10% (P ≤ 0.05), 75.66% (P ≤ 0.001) & 91.05% (P ≤ 0.001) contents respectively, in a dose dependent manner following 21 days treatment of plant extract. Apart from this, the levels of total cholesterol 40.07% (P ≤ 0.01), 62.36% (P ≤ 0.001) and 80.02 (P ≤ 0.001) and triglycerides 52.88% (P ≤ 0.05), 68.51% (P ≤ 0.01) & 85.22% (P ≤ 0.001) were restored dose- dependently, after the *E. littorale* supplementation at the doses of 125, 250 and 500 mg/kg b wt/day, in CCl₄-treated rats (Group IV, V and VI).

Table 2 shows statistically significant (P < 0.001) alterations in serum -AST, ALT, γ-GTP, LDH, ALP, ACP, SDH, total bilirubin, total protein and albumin levels after CCl₄ intoxication in comparison to normal controls. Concurrent

administration of CCl₄ and *E. littorale* extract at the doses of 125, 250 and 500 mg/kg b wt/day to rats, brought about a remarkable restoration in the levels of AST 43.45% (P ≤ 0.001), 64.82% (P ≤ 0.001) & 92.25% (P ≤ 0.001); ALT 55.06% (P ≤ 0.001), 67.32% (P ≤ 0.001) & 91.31% (P ≤ 0.001); γ-GTP 54.90% (P ≤ 0.001), 76.71% (P ≤ 0.001) & 87.63% (P ≤ 0.001); LDH 52.35% (P ≤ 0.001), 67.86% (P ≤ 0.001) & 91.94% (P ≤ 0.001); ALP 42.63% (P ≤ 0.05), 61.46% (P ≤ 0.01) & 84.62% (P ≤ 0.001); ACP 40.69% (P ≤ 0.05), 66.70% (P ≤ 0.001) & 84.92% (P ≤ 0.001); SDH 57.92% (P ≤ 0.001), 74.57% (P ≤ 0.001) & 90.54% (P ≤ 0.001); total bilirubin 52.14% (P ≤ 0.05), 68.38% (P ≤ 0.01) & 91.00% (P ≤ 0.001); total protein 41.38% (P ≤ 0.01), 57.47% (P ≤ 0.001) & 99.71% (P ≤ 0.001); albumin 42.73% (P ≤ 0.05), 59.54% (P ≤ 0.001) & 84.09% (P ≤ 0.001) respectively, in a dose dependent manner at 21 days treatment of plant extract (Group IV, V & VI).

Silymarin was used as a standard drug for comparison with *E. littorale* observations. Silymarin at the dose of 125 mg/kg b wt/day to rats, remarkably supported the antioxidant defense system like GSH 89.89% (P ≤ 0.001); GST 82.08% (P ≤ 0.001); GPx 87.32% (P ≤ 0.001); SOD 86.85% (P ≤ 0.001); CAT 73.48% (P ≤ 0.001); Vit. C 70.62% (P ≤ 0.001) and LPO 98.88% (P ≤ 0.001) with concomitant decreased in the levels of total cholesterol 87.09% (P ≤ 0.001) and triglycerides 91.95% (P ≤ 0.001) in the liver at 21 days of treatment, as shown in the Table 1 (Group III).

Silymarin treatment at the dose of 125mg/kg/b wt/day to rats, restored all the serum marker enzymes like AST 96.40% (P ≤ 0.001); ALT 93.07% (P ≤ 0.001); γ-GTP 91.90% (P ≤ 0.001); LDH 96.41% (P ≤ 0.001); ALP 88.65% (P ≤ 0.001); ACP 86.44% (P ≤ 0.001); SDH 94.34% (P ≤ 0.001) and serum-total bilirubin 96.58% (P ≤ 0.001); total protein 98.85% (P ≤ 0.001) and albumin 86.82% (P ≤ 0.001) contents to the normal levels following 21 days of treatment (Group III ; Table 2).

Histoarchitectural examination of the liver sections of rats treated with CCl₄ showed intense centrilobular necrosis and vacuolization in the group II compared with group I (Figure 1 and 2). The rats treated with silymarin and *E. littorale* extract, along with CCl₄, showed signs of protection against CCl₄ to a considerable extent as evident from formation of normal hepatic cords and absence of necrosis and vacuoles in the liver histology in the group III, IV, V & VI (Figure 3, 4, 5 and 6).

DISCUSSION

The findings of the present investigations are based on the hepatomodulation ability of *E. littorale* extract to reduce the injurious effects caused by CCl₄ because hepatic cells appear to participate in a variety of enzymatic metabolic activities. Metabolically, CCl₄ is a well known model compound for producing chemical hepatic injury, requires biotransformation by the hepatic microsomal cytochrome

Table 1. Showing hepatomodulation through antioxidant defense system and fat metabolism by Silymarin and different doses of *E. littorale* extract against oxidative stress in male rats.

Group	GSH		GST		GP _x		SOD		Catalase		Vitamin-C		LPO		Total Cholesterol		Triglycerides	
	n mole/g tissue	% modulation	μ mole of CDNB-GSH conjugated formed/min/mg protein	% modulation	n mole of NADPH consumed / min/mg protein	% modulation	μ mole/mg protein	% modulation	μ mole H ₂ O ₂ consumed/min/mg protein	% modulation	mg/g tissue	% modulation	n mole MDA/mg tissue	% modulation	mg/g tissue	% modulation	mg/g tissue	% modulation
Normal (vehicle treated) (Gp. I)	3.31±0.18		4.56±0.26		9.01±0.50		8.34±0.40		62.48±3.44		2.88±0.26		3.34±0.39		7.46±0.37		10.89±0.91	
CCl ₄ (0.2 ml/kg.b.wt/ twice a week) (Gp. II)	1.43±0.09 ^a		2.16±0.14 ^a		4.75±0.22 ^a		3.93±0.17 ^a		33.44±2.63 ^a		0.94±0.08 ^a		10.49±0.85 ^a		15.67±0.74 ^a		19.21±1.15 ^a	
CCl ₄ + Silymarin (125 mg/kg.b.wt./day) (Gp. III)	3.12±0.11 ^a	89.89	4.13±0.20 ^a	82.08	8.47±0.28 ^a	87.32	7.76±0.34 ^a	86.85	54.78±2.92 ^a	73.48	2.31±0.22 ^a	70.62	3.42±0.26 ^a	98.88	8.52±0.33 ^a	87.09	11.56±0.52 ^a	91.95
CCl ₄ + <i>E. littorale</i> extract (125 mg/kg.b.wt./day) (Gp. IV)	2.24±0.12 ^a	43.08	2.86±0.18 ^b	29.17	5.66±0.23 ^c	21.36	4.66±0.26 ^c	16.55	43.34±3.17 ^c	34.09	1.67±0.13 ^a	37.63	7.48±0.61 ^c	42.10	12.38±0.68 ^d	40.07	14.81±0.87 ^c	52.88
CCl ₄ + <i>E. littorale</i> extract (250mg/kg.b.wt./day) (Gp. V)	2.87±0.10 ^a	76.59	3.55±0.22 ^a	57.92	6.92±0.25 ^a	50.94	6.32±0.29 ^a	54.19	50.33±3.03 ^d	58.16	1.98±0.23 ^d	53.61	5.08±0.25 ^a	75.66	10.55±0.56 ^a	62.36	13.51±0.57 ^d	68.51
CCl ₄ + <i>E. littorale</i> extract (500mg/kg.b.wt./day) (Gp. VI)	3.10±0.07 ^a	88.83	4.05±0.21 ^a	78.75	8.15±0.24 ^a	79.81	7.54±0.30 ^a	81.86	54.52±3.12 ^a	72.59	2.12±0.18 ^a	60.82	3.98±0.26 ^a	91.05	9.10±0.48 ^a	80.02	12.12±0.42 ^a	85.22

Levels of significance : Data are mean ± SEM (n=6)

a = P ≤ 0.001
 a = P ≤ 0.001
 a = P ≤ 0.001; b = P ≤ 0.01; c = P ≤ 0.05

Gp. II compared with control (Gp. I).
 Gp. III compared with Gp. II
 Gp. IV, V and VI compared with Gp. II.

Table 2. Showing hepatomodulation through serum marker parameters by Silymarin and different doses of *E. littorale* extract against oxidative stress in male rats.

Group	AST		ALT		γ -GTP		LDH		ALP		ACP		SDH		Total bilirubin		Total protein		Albumin	
	(U/ml)	(%) modulation	(U/ml)	(%) modulation	(IU/l)	(%) modulation	(U/ml)	(%) modulation	(KAU)	(%) modulation	(KAU)	(%) modulation	(U/ml)	(%) modulation	(mg/dl)	(%) modulation	(g/dL)	(%) modulation	(g/dL)	(%) modulation
Normal (vehicle treated) (Gp. I)	45.30± 2.40		37.19± 2.20		5.73± 0.35		102.84± 2.89		8.81± 0.90		4.84± 0.68		39.89± 2.59		0.65± 0.09		6.56± 0.31		3.63± 0.32	
CCl ₄ (0.2 ml/kg.b.wt/ twice a week) (Gp. II)	133.29± 3.83 ^a		129.84± 3.45 ^a		33.38± 1.76 ^a		195.81± 3.98 ^a		26.17± 2.18 ^a		14.72± 1.18 ^a		129.36± 4.67 ^a		1.82± 0.17 ^a		3.08± 0.27 ^a		1.43± 0.17 ^a	
CCl ₄ + Silymarin (125 mg/kg.b.wt./day) (Gp. III)	48.47± 2.72 ^a	96.40	43.61± 2.55 ^a	93.07	7.97± 0.50 ^a	91.90	106.18± 2.20 ^a	96.41	10.78± 0.88 ^a	88.65	6.18± 0.77 ^a	86.44	44.95± 2.51 ^a	94.34	0.69± 0.12 ^a	96.58	6.52± 0.28 ^a	98.85	3.34± 0.14 ^a	86.82
CCl ₄ + <i>E. littorale</i> extract (125 mg/kg.b.wt./day) (Gp. IV)	95.06± 3.24 ^a	43.45	78.83± 2.75 ^a	55.06	18.20± 1.12 ^a	54.90	147.14± 3.45 ^a	52.35	18.77± 1.25 ^c	42.63	10.70± 0.82 ^c	40.69	77.54± 3.18 ^a	57.92	1.21± 0.16 ^c	52.14	4.52± 0.29 ^b	41.38	2.37± 0.27 ^c	42.73
CCl ₄ + <i>E. littorale</i> extract (250mg/kg.b.wt./day) (Gp. V)	76.25± 2.31 ^a	64.82	67.47± 2.61 ^a	67.32	12.17± 0.95 ^a	76.71	132.72± 2.35 ^a	67.86	15.50± 1.14 ^b	61.46	8.13± 0.48 ^a	66.70	62.64± 2.56 ^a	74.57	1.02± 0.13 ^b	68.38	5.08± 0.33 ^a	57.47	2.74± 0.18 ^a	59.54
CCl ₄ + <i>E. littorale</i> extract (500mg/kg.b.wt./day) (Gp. VI)	52.12± 2.10 ^d	92.25	45.24± 2.32 ^d	91.31	9.15± 0.87 ^d	87.63	110.33± 2.23 ^a	91.94	11.48± 1.07 ^a	84.62	6.33± 0.42 ^d	84.92	48.35± 2.39 ^a	90.54	0.76± 0.09 ^d	91.00	6.55± 0.29 ^a	99.71	3.28± 0.17 ^a	84.09

Levels of significance:

a = P < 0.001

a = P < 0.001

a = P < 0.001; b = P < 0.01; c = P < 0.05

Data are mean ± SEM (n=6)

Gp. II compared with control (Gp. I).

Gp. III compared with Gp. II

Gp. IV, V & VI compared with Gp. II.

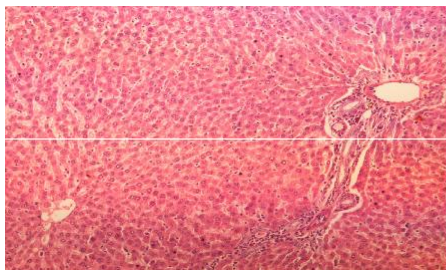


Figure 1. Photomicrograph of control rat liver section showing well brought central vein, hepatic cells with preserved cytoplasm and prominent nucleus at H & E X100

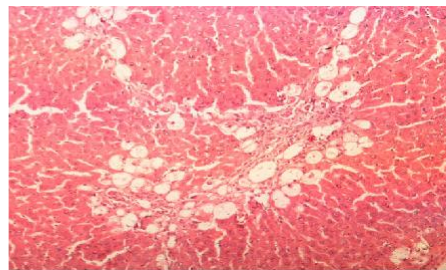


Figure 2. Photomicrograph of rat liver section with CCl₄ treatment showing marked steatosis of the hepatocytes with ballooning degeneration & distended portal vein, mild periportal fibrosis and necrosis at H & E X100

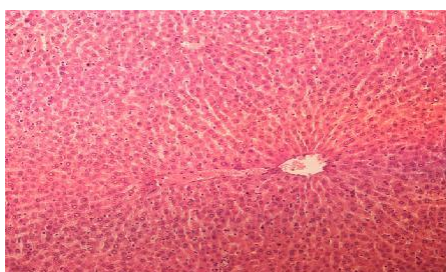


Figure 3. - Photomicrograph of rat liver section of CCl₄ + *Silymarin* (125 mg/kg b wt), showing moderately brought central vein, hepatic cells with preserved cytoplasm and prominent nucleus at H & E X100

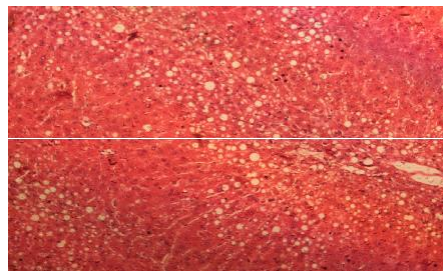


Figure 4. Photomicrograph of rat liver section of CCl₄ + *E. littorale* extract (125 mg/kg b wt), showing moderately regeneration in hepatocellular architecture at H & E X100

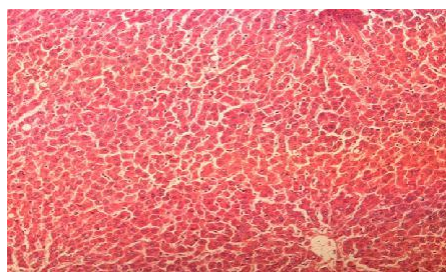


Figure 5. Photomicrograph of rat liver section of CCl₄ + *E. littorale* extract (250 mg/kg b wt), showing considerable reduction in necrosis and fatty changes with pyknotic nuclei and cytoplasmic clearing at H & E X100

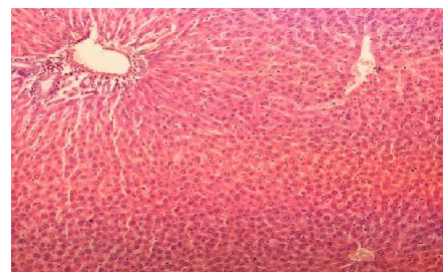


Figure 6. Photomicrograph of rat liver section of CCl₄ + *E. littorale* extract (500 mg/kg b wt), showing moderately brought central vein, hepatic cell with preserved cytoplasm and prominent nucleus at H & E X100

P 450 to produce hepatotoxic metabolites, namely trichloromethyl free radicals (CCl₃⁻ and/or CCl₃OO⁻) (Brent and Rumack, 1993). Free radicals are involved in the oxidative stress that induced liver injury. Oxidative stress of hepatocytes mainly indicated by lipid peroxidation (LPO) because LPO occurs in membranes, where the content of unsaturated fatty acids is relatively high. Peroxidation of membrane lipids arising out of oxidative damage in intact cells results in decreased fluidity, inactivation of membrane bound enzymes and receptors and changes in

nonspecific ion permeability (Ramachandran *et al.*, 2002).

In the present investigation, the measurement of lipid peroxidation is a convenient method to monitor oxidative cell damage. Inhibition of LPO has been observed in silymarin and *E. littorale* extract treated groups due to their antioxidant and free radical scavenging activities through re-establishment of biomembrans of hepatic parenchymal cells.

The depletion of GSH promotes generation of reactive oxygen species and oxidative stress with cascade of eff-

ects thereby affecting functional as well as structural integrity of cell and organelle membranes. (De Leve et al., 1996). The elevated level of GSH with silymarin and *E. littorale* extract dose- dependently protects cellular proteins against oxidation through glutathione redox cycle and also directly detoxifies reactive oxygen species and/or neutralizes reactive intermediate species generated from exposure to CCl₄.

The decreased GST activity in CCl₄ exposure found to be enhanced by silymarin and *E. littorale* extract significantly in a dose-dependent manner. The elevated level of GST by the extract may have facilitated the conjugation reaction of xenobiotic metabolism and may have increased the availability of non-critical nucleophiles for inactivation of electrophiles (Bharali et al., 2003) and therefore might be playing a major role in hepatomodulation against oxidative stress.

Reactive oxygen species and free radicals are involved in oxidative stress-induced liver injury by CCl₄. The restoration of the levels of decreased antioxidant profiles i.e. GPx, SOD, CAT and Vit-C by silymarin and *E. littorale* extract may be attributed to have biological significance in eliminating reactive free radicals that may affect the normal functioning of cells (Singh, 2000).

The oxidative stress induced severe liver injury by CCl₄ is also increase the peripheral fat metabolism resulting enhance hepatic triglyceride synthesis leads to excess total cholesterol accumulation (Subrata de et al., 1994). The silymarin and *E. littorale* extract supplementation in our study was potentially effective in reduction of excess total cholesterol accumulation and hepatic triglyceride synthesis.

Experimental animals exposed with CCl₄, transaminases activity (AST, ALT), ALP, ACP, γ -GTP, LDH and SDH were increased remarkably in plasma by the release of these enzymes from hepatic paranchymal cells, which were indicating a considerable hepatocellular injury by oxidative stress (Bishayee et al., 1995; Achliya et al., 2004). Oral treatment with silymarin and *E. littorale* extract attenuated these increased enzyme activities produced by CCl₄ and a subsequent recovery towards normalization of these enzymes strongly suggests the possibility of silymarin and *E. littorale* extract being able to improve the condition of the hepatocytes so as to cause accelerated regeneration of paranchymal cells, thus protecting against membrane fragility decreasing the leakage of marker enzymes into the circulation stabilization of serum-total bilirubin, total protein and albumin levels through the administration of silymarin and the extract are further a clear indication of the improvement of the functional status of the hepatic cells (Bishayee et al., 1995; Achliya et al., 2004).

Thus the results of the present investigation are clearly demonstrate that various biochemical changes, produced in the serum and liver of rats by CCl₄ treatment, were significantly restored by the oral administration of silymarin and by *E. littorale extract* dose dependently. These findings were further confirmed by a comparative histo-

architectural examinations of the liver from different groups of rats. Various pathological lesions observed i.e. marked steatosis, pseudolobulation, ballooning degeneration, periportal fibrosis etc. in group II, and were dose-dependently moderate reduction in group III, IV, V & VI.

Conclusion

It may be concluded that the *E. littorale* extract exhibited significant hepatomodulation against oxidative stress-induced liver injury by CCl₄ in rats through antioxidant potential and free radical scavenging activities alongwith reduction of fat metabolism.

Further, isolation and characterization of active principles of *E. littorale* and their chemical nature responsible for hepatomodulation are in progress and will be reported elsewhere.

ACKNOWLEDGEMENT

The authors are grateful to Head, Department of Zoology and Prof. N.K. Lohiya, Coordinator, CAS, Department of Zoology, University of Rajasthan, Jaipur for providing necessary facilities and UGC Regional Centre, Bhopal (India) for financial support.

REFERENCES

- Achliya GS, Wadodkar SG, Dorle AK (2004). Evaluation of hepatoprotective effect of Amalkadi Ghrita against carbon tetrachloride induced hepatic damage in rats. *J. Ethnopharmacol.* 90 : 229-232.
- Aebi H (1984). Catalase, *in vitro*. In : colowick, S.P., kaplan, N.O., (Eds.), *Methods in Enzymology*, Vol. 105. Academic Press, New York, pp. 121-126.
- Anonymous (2002). *Wealth of India, Raw Material*, New Delhi, Vol. 5. Publication and Information Directorate, CSIR, pp. 176-177.
- Bharali R, Tabassum J, Azad MRH (2003). Chemomodulatory effect of *Moringa oleifera* Lam. on hepatic carcinogen metabolising enzymes, antioxidant parameters and skin papillomagenesis in mice. *Asian Pacific J. Cancer Prevention* 4: 131-139.
- Bishayee A, Sarkar A, Chatterjee M (1995). Hepatoprotective activity of carrot (*Daucus carota* L.) against carbon tetrachloride intoxication in mouse liver. *J. Ethnopharmacol.* 47: 69-74.
- Blumenthal M (2002). Herb sales down in mainstream market, up in natural food stores. *Herbalgram.* 55: 60-61.
- Brent JA, Rumack BH (1993). Role of free radicals in toxic hepatic injury II. *Clin. Toxicol.* 31: 173-196.
- De Leve LD, Wang X, Kuhlenskamp JF, Kaplowitz N (1996). Toxicity of azathioprine and monocrotaline in murine sinusoidal endothelial cells and hepatocytes : the role of glutathione and relevance to hepatic venoocclusive disease. *Hepatology* 23: 589-599.
- Flora K, Hahn M, Rosen H, et al. (1998). Milk thistle (*Silybum marianum*) for the therapy of liver disease. *Am. J. Gastroenterol.* 93 : 139-143.
- Gonzalez FJ (1988). The molecular biology of cytochrome P 450s. *Pharmacological Reviews* 40 : 243-288.
- Gottfried SP, Rosenberg B (1973). Improved manual spectrophotometric procedure for determination of triglycerides. *Clin. Chem.* 19: 1077-1078.
- Habig WH, Pabst MJ, Jacoby WB (1974). Glutathione-s-transferase-the first step in mercapturic acid formation. *J. Biol. Chem.* 249: 7130-7139.
- Karen MPH, Kris MD (2005). A review of *Silybum marianum* (milk histle)

- as a treatment for alcohol liver disease. *J. Clin. Gastroenterol.* 39: 520-528.
- Lee KJ, Woo ER, Choi CY, Shin DW, Lee DG, You HJ, Jeong HG (2004). Protective effect of acteoside on carbon tetrachloride induced hepatotoxicity. *Life Sciences* 74: 1051-1054.
- Marklund S, Marklund G (1974). Involvement of superoxide anion radical in auto-oxidation of pyrogallol and a convenient assay for superoxide dismutase. *Eur. J. Biochem.* 47: 469-474.
- Moron MS, Depierre JW, Mannervick B (1979). Levels of glutathione, glutathione reductase and glutathione-s-transferase activities in rat lung and liver. *Biochem. Biophys. Acta* 582: 67-78.
- Murali B, Upadhyaya UM, Goyal RK (2002). Effect of Chronic treatment with *Enicostemma littorale* in non-insulin-dependent diabetic (NIDDM) rats. *J. Ethnopharmacol.* 81: 199-204.
- Ohkawa H, Ohishi N, Yagi K (1979). Assay for lipid peroxidation in animal tissue by thiobarbituric acid reaction. *Anal Biochem.* 95: 351-358.
- Paglia DE, Valentine WM (1967). Studies on the quantitative and qualitative characterization of erythrocyte glutathione peroxidase. *J. Lab. Clin. Med.* 70: 158-169.
- Ramachandran HD, Narasimhamurthy K, Raina PL (2002). Effect of oxidative stress on serum and antioxidant enzymes in liver and kidney of rats and their modulation through dietary factors. *Indian J. Exp. Biol.* 40: 1010-1015.
- Roe JH, Kuether CA (1943). The determination of ascorbic acid in whole blood and urine through 2,4-DNPH derivative of dehydroascorbic acid. *J. Biochem.* 147: 399-407.
- Senthilkumar KTM, Rajkapoor B, Kavimani S (2005). Protective effect of *Enicostemma littorale* against CCl₄-induced hepatic damage in rats. *Pharmaceutical Biol.* 43: 485-487.
- Singh RP, Padmanathi B, Rao AR (2000). Modulatory influence of *Adhatoda vesica* leaf extract on the enzymes of xenobiotic metabolism, antioxidant status and lipid peroxidation in Mice. *Mol. Cell Biochem.* 213: 99-109.
- Subrata De, Ravishankar B, Bhavsar GC (1994). An investigation on the hepatoprotective activity of *Gymnosporia montana*. *Plant. Med.* 60: 301-304.
- Vijayvargia R, Kumar M, Gupta S (2000). Hypoglycemic effect of aqueous extract of *Enicostemma littorale* Blume on alloxan induced diabetes mellitus in rats. *Indian J. Exp. Biol.* 38: 781-784.
- William MD, Raymond MD (1990). Carbon tetrachloride hepatotoxicity : An example of free radical-mediated injury. *Seminar in liver Disease.* 10: 279-284.
- Zlatkis A, Zak B, Boyle AJ (1953). A new method for the direct determination of cholesterol. *J. Lab. Clin. Med.* 41: 486-492.