

Case Report

Ocular myasthenia with thyroid associated ophthalmopathy in subclinical Graves' disease

Deep Dutta[#], Meha Sharma*, Nayjyoti Barman, Krishna Biswas

Consultant Clinical Neurophysiologist, Ibn-Sina Hospital, Kuwait Clinical Tutor in Neurology

Received 14 July, 2012; Accepted 15 September, 2012

Ocular myasthenia in Graves' disease is very rare with less than 10 cases reported. We present a clinically euthyroid lady with features of thyroid associated ophthalmopathy (TAO) who had mild ptosis, external ophthalmoplegia, firm goiter and subclinical hyperthyroidism. Hertel exophthalmometry confirmed exophthalmos. CT orbit revealed thickening of bilateral inferior, medial and superior recti. Anti-thyroid peroxidase antibody was positive (154IU/ml; normal<40IU/ml). Repetitive nerve stimulation test (RNST) of bilateral nasalis muscle showed decremental response, more prominent on the left side. Electrodiagnostic screening for concomitant myopathy or neuropathy was unremarkable. A subsequent positive neostigmine test and a positive anti-acetylcholine receptor antibody (1.46nmol/L; normal<0.5nmol/L) lead to the diagnosis of ocular myasthenia with TAO and subclinical Graves' disease. Ptosis and ophthalmoplegia improved with pyridostigmine and carbimazole. She was doing well even after 2 years of follow up. Any patient of TAO with ptosis and disproportionate ophthalmoplegia should be evaluated to rule out ocular myasthenia. The idea of presenting this case is to highlight that TAO and ocular myasthenia can co-exist and one has to always keep a strong clinical suspicion, as lack of treatment of even clinically silent Graves' disease in a patient with myasthenia can aggravate the weakness.

Key words: ocular myasthenia, thyroid associated ophthalmopathy, ptosis, Graves disease, subclinical hyperthyroidism

INTRODUCTION

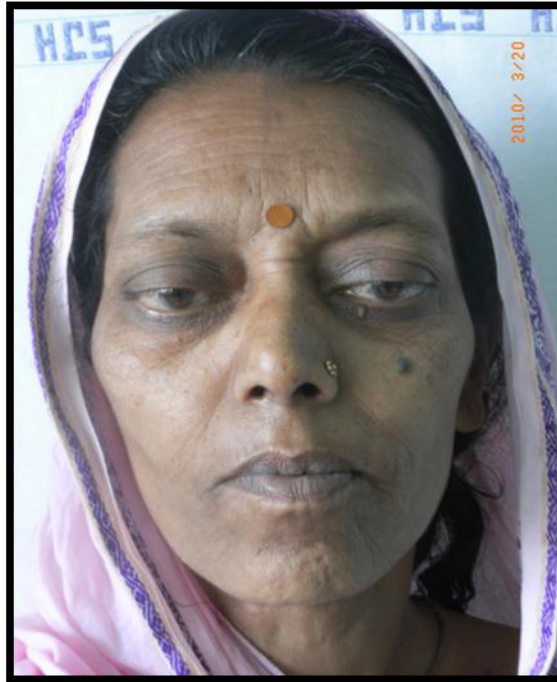Hyperthyroidism occurs in 3-8% of patients with myasthenia (Drachman, 2008). However occurrence of ocular myasthenia in a patient with Graves' disease is uncommon with ten cases being reported till date (Bixenman, 1988; Kusuhara, 2003; Koves, 2009; Raef, 1990; Yaman, 2003; Zouvelou, 2008) of which 4 patients had clinically silent Graves' disease with ocular myasthenia (Bixenman, 1988; Kusuhara, 2003; Raef, 1990; Zouvelou, 2008). Clinically silent Graves' ophthalmopathy with ocular myasthenia is a diagnostic challenge as one of the diagnoses may be missed due to significant overlap of the clinical ocular manifestations in both the disorders. We present a 65 year lady with clinically silent Graves' disease and ocular myasthenia.

CASE REPORT

Sixty-five year old lady presented with eye pain, grittiness, redness and watering of a year duration. The symptoms were more troublesome in her left eye. She had bilateral proptosis, more prominent on the left side, bilateral complete external ophthalmoplegia with mild ptosis more prominent in the left eye, without any evidence of inflammation of conjunctiva, eye lids or the caruncle (Clinical activity score zero) (Picture-1). Pupillary response was normal. Intraocular pressure in left and right eyes was 11 and 12 mm Hg respectively. Exophthalmometry (Hertel exophthalmometer) gave readings of 21 and 20 mm in left and right eye respectively (normal< 20 mm) with distance on the scale measuring 101mm. Ophthalmoscopy was normal. She had Stage-Ib firm non-tender diffuse goiter. She had no clinical features suggestive of thyrotoxicosis. She did not have any evidence of bulbar and neck

*corresponding authors' Email: deepdutta2000@yahoo.com

Picture-1: Patient profile showing bilateral proptosis with mild ptosis (more prominent in the left eye) when they eyes are in the neutral position



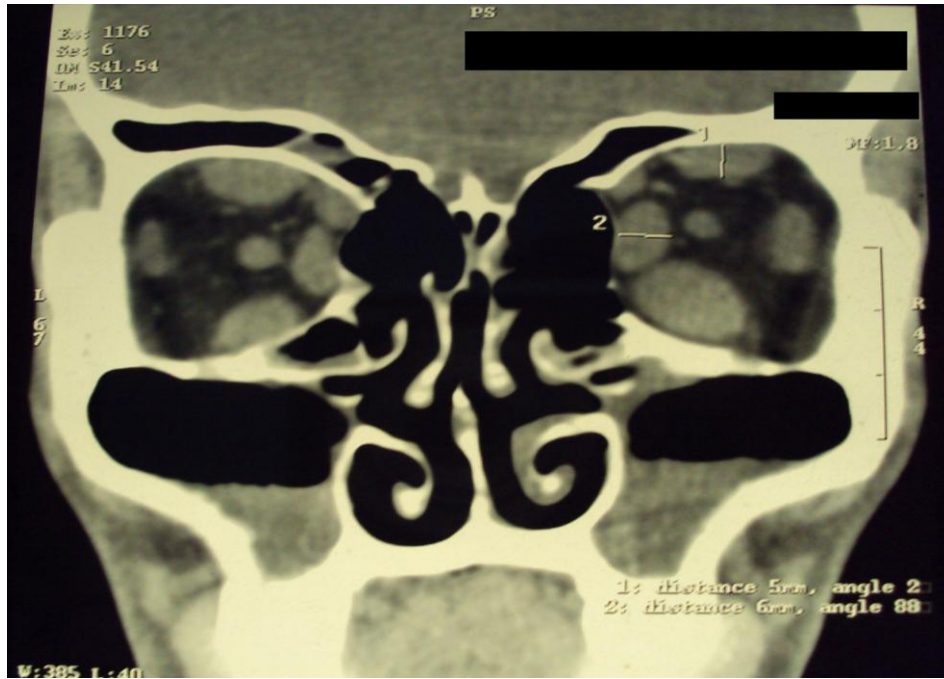
muscles involvement. Power in all 4 limbs were normal. She was a chronic smoker, smoking 1-2 packs of “bidi” (thin indigenous Indian cigarette filled with tobacco flakes wrapped in tendu leaves) since 20 years of age. She gave informed written consent for the use of her pictures, clinical details and investigations for scientific purposes.

Investigations were significant for low TSH 0.05 mU/L (0.4-4.5 mU/L), normal T₃ 154 ng/dl (60-181 ng/dl) and a normal T₄ 12.4 µg/dl (8.2-12.8µg/dl). Anti-TPO antibody was 154 IU/ml (normal <37 IU/ml). Her 2 hour and 24 hour radioactive iodine uptake was 6.8% (normal:5-15%) and 30.6% (normal: 15-35%) respectively and thyroid scan was suggestive of diffuse radioactive uptake in bilateral lobes of the gland. Fine needle aspiration cytology (FNAC) of thyroid showed numerous follicles with decreased colloid, infiltration of lymphocytes and fire-flare appearance. Contrast enhanced computerized tomography (CECT) orbit showed exophthalmos with thickening of all the extraocular muscles, most prominent in bilateral inferior recti followed by medial recti and superior recti (Picture-2a, 2b). CECT thorax was normal. Repetitive nerve stimulation test (RNST) of bilateral nasalis muscle showed decremental response, more prominent in the right nasalis muscle, suggestive of myasthenia (Picture-3a,3b). Comparing the fifth action potential with the first action potential, there was a 49% decrease in the amplitude and 28% decrease in the area of the

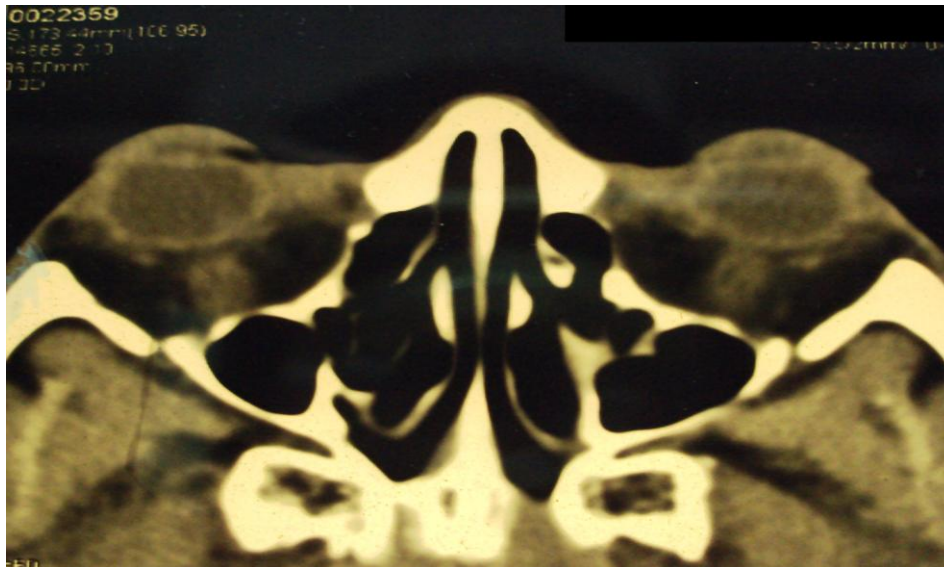compound muscle action potential (CMAP) of right nasalis muscle. A 19% decrease in amplitude with a 24% decrease in area of CMAP of left nasalis was also noted. Any decrement of greater than 10% in considered significant, with the decrement in area considered to be more specific than that of amplitude in diagnosing myasthenia (Meriggioli, 2004). Electrodiagnostic screening for concomitant myopathy or neuropathy was unremarkable. The patient showed improvement in ptosis and external ophthalmoplegia with neostigmine test. Anti-acetylcholine receptor antibody (anti-AchR-Ab) level was elevated 1.46nmol/L (normal <0.5 nmol/L).

Patient was started on pyridostigmine (Myestin, VHB, Mumbai) initially 60 mg thrice daily which was increased to 60 mg four times per day. She also received carbimazole (Thyrocab, Abbott, Mumbai) 10mg thrice daily which was subsequently tapered and stopped 2 months back. Her ptosis improved and there was partial improvement in external ophthalmoplegia in all directions, mainly in the vertical axis. Exophthalmos was not affected by the therapy. She received 2% hydroxypropylmethylcellulose eye drops (Viscomet, Sun, Mumbai) which improved her eye symptoms. Last evaluated 2 years after the initial diagnosis, patient was clinically and biochemically euthyroid, ptosis had improved with marked improvement in ocular movements with mild residual external ophthalmoplegia mainly in the horizontal axis.

Picture-2a: Computerized tomography (CT) orbit showing bilateral thickened extra-ocular muscles of both eyes predominantly involving the inferior recti, medial recti and superior recti;
Picture-2b: CT orbit showing bilateral exophthalmos



Picture-2b: Computerized tomography (CT) orbit showing bilateral thickened extra-ocular muscles of both eyes predominantly involving the inferior recti, medial recti and superior recti;
Picture-2b: CT orbit showing bilateral exophthalmos

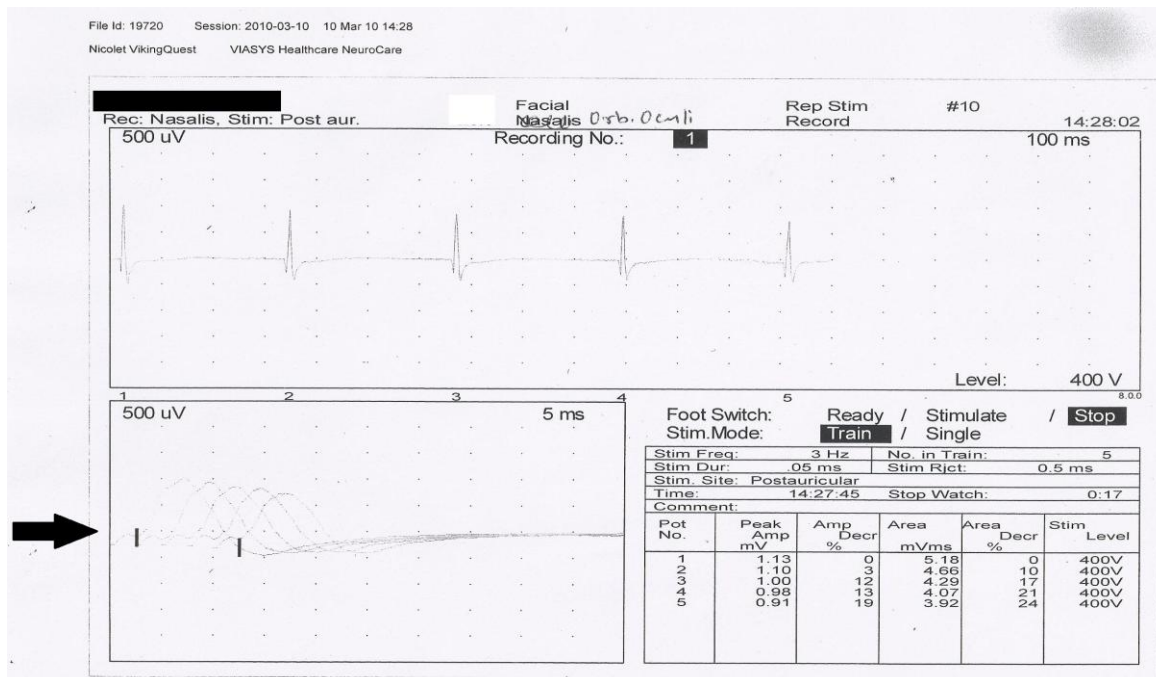


DISCUSSION

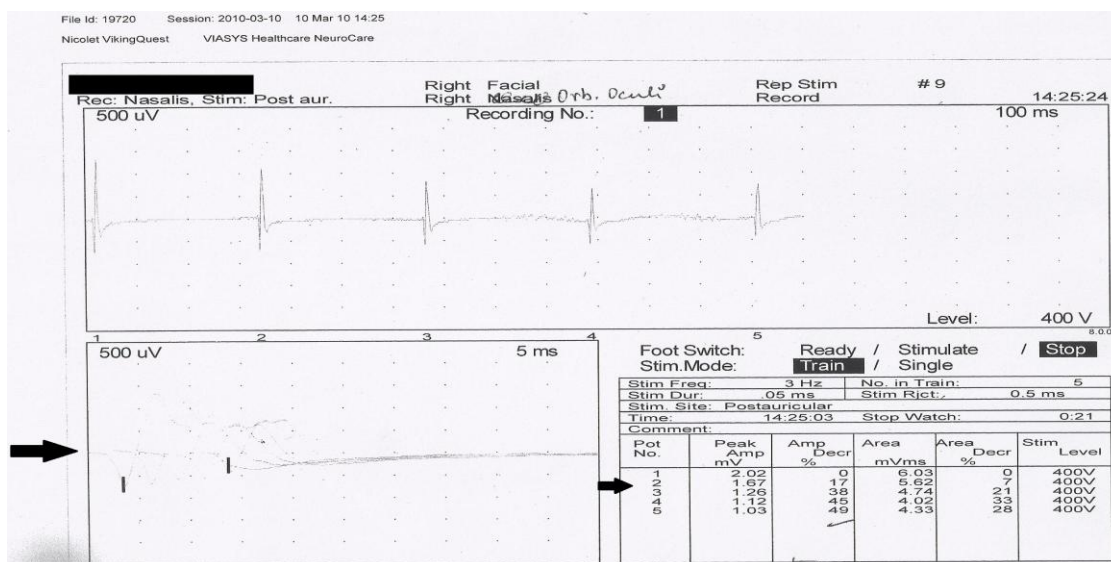
Restrictive extra ocular muscle weakness has been observed both in patients with thyroid associated

ophthalmopathy (TAO) and ocular myasthenia, but ptosis is absent in TAO (Luchanok, 2008). Ptosis in a patient with Graves’ disease suggests the coexistence of myasthenia gravis. Orbicularis oculi weakness in

Picture-3a: Repetitive nerve stimulation test (RNST) of left nasalis muscle showing a 24% decrease in area of compound muscle action potential (CMAP) of the fifth potential as compared to the first; **3b:** RNST of right nasalis muscle showing 28% decrease in area of CMAP of the fifth potential as compared to the first.



Picture-3b: Repetitive nerve stimulation test (RNST) of left nasalis muscle showing a 24% decrease in area of compound muscle action potential (CMAP) of the fifth potential as compared to the first; **3b:** RNST of right nasalis muscle showing 28% decrease in area of CMAP of the fifth potential as compared to the first.



combination with ptosis or external ophthalmoparesis is a strong indicator of myasthenia gravis (Barton, 2000). The presence of exophthalmos and firm thyromegaly in

our patient lead us to suspect an underlying autoimmune thyroid disease. She did not present with any overt symptoms of thyrotoxicosis, but biochemically

she was sub-clinically hyperthyroid. Thyroiditis was ruled out due to normal diffuse uptake on radio-iodine study.

FNAC evidence of thyroid hyperfunction in the background of normal diffuse uptake on radio-iodine study and ocular involvement confirmed the diagnosis of clinically silent Graves' disease.

External ophthalmoplegia was disproportionately severe in our patient as compared to the exophthalmos and eye symptoms of TAO. The presence of mild ptosis and the associated severe external ophthalmoplegia in the absence of bulbar, neck muscles and limb weakness made us suspect ocular myasthenia.

Positive RNST of bilateral nasalis muscles and neostigmine test in the presence of positive anti-AchR antibodies confirmed the diagnosis of ocular myasthenia. Neostigmine was used for stimulation as edrophonium is not available in this part of the world.

Estimation of anti-TSH receptor antibody could not be done in our patient due to financial constraints and is one of the limitations of this report.

RNST is not the best test for diagnosing myasthenia cause of its low sensitivity of 60%. Single fibre EMG (SFEMG) is the most sensitive test for the diagnosis of neuromuscular diseases including myasthenia. However it is less specific than RNST.

SFEMG was not necessary in our patient as RNST was diagnostic of ocular myasthenia.

Fifty percent of patients presenting with ocular myasthenia develop generalized weakness within 6 months and up to 80% will generalize within 2 years (Kupersmith, 2003). Patient with ocular myasthenia without any progression for 2 years, are likely to have symptoms restricted to the ocular muscles there after (Kupersmith, 2003). Our patient had improvement of symptoms with pharmacotherapy, and till 2 years of follow up she was asymptomatic and did not complain of any limb weakness. She did not receive any immunosuppressive therapy like corticosteroids as she had only ocular myasthenia and responded well to pyridostigmine supplementation. Corticosteroid therapy at this age is associated with significant morbidity including osteoporosis.

To summarize we presented a lady with ocular myasthenia with TAO who had subclinical Graves' disease who responded well to medical management. The idea of presenting this case is to highlight that when TAO and ocular myasthenia co-exist, diagnosis becomes a challenge due to masking of the features and a strong clinical suspicion for the other in presence of one should be kept, as treatment is different for the two pathologies, and lack of treatment of even clinically silent Graves' disease in a patient with myasthenia can aggravate the weakness.

REFERENCES

- Barton JJ, Fouladvand M (2000). Ocular aspects of myasthenia gravis. *Semin Neurol*.20:7–20.
- Bixenman WW, Buchsbaum HW. Multiple sclerosis, euthyroid restrictive Graves' ophthalmopathy and myasthenia gravis (1988). *Graefe's Arch Clin Exp Ophthalmol*. 226: 168-171.
- Drachman D, Myasthenia gravis and other diseases of neuromuscular junction. In: Fauci A, Braunwald E, Kasper D, Hauser L (2008). *Harrison's Principles of Internal Medicine*. 17th Edition Volume-2, McGraw Hill. 2675
- Koves IH, Cameron FJ, Kornberg AJ (2009). Ocular myasthenia gravis and Graves disease in a 10-year-old child. *J. Child Neurol*.24(5):615-7.
- Kupersmith MJ, Latkany R, Homel P (2003). Development of generalized disease at 2 years in patients with ocular myasthenia gravis. *Arch Neurol*. 60:243–248.
- Kusuhara T, Nakajima M, Imamura A (2003). Ocular myasthenia gravis associated with euthyroid ophthalmopathy. *Muscle Nerve*.28(6):764-6.
- Luchanok U, Kaminski HJ (2008). Ocular myasthenia: diagnostic and treatment recommendations and the evidence base. *Curr Opin Neurol*.21(1):8-15
- Meriggioli MN, Sanders DB (2004). Myasthenia gravis: Diagnosis. *Seminars in Neurology*. 24(1):31-39
- Raef H, Ladinsky M, Arem R (1990). Concomitant euthyroid Graves' ophthalmopathy and isolated ocular myasthenia gravis *Postgrad. Med. J.* .66:849-52
- Yaman A, Yaman H (2003). Ocular myasthenia gravis coincident with thyroid ophthalmopathy. *Neurol India*.51(1):100-1.
- Zouvelou V, Potagas C, Karandreas N, Rentzos M, Papadopoulou M, Zis VP, Vassilopoulos D (2008). Concurrent presentation of ocular myasthenia and euthyroid Graves ophthalmopathy: a diagnostic challenge. *J. Clin. Neurosci*.15(6):719-20