

Full Length Research Paper

Ultra structural study of gentamicin and ofloxacin effect on testis tissue in rats: Light and transmission electron microscopy

Arash Khaki^{1*}, Mafat Ghaffari Novin², AmirAfshin Khaki³, Fatemeh Fathiazad⁴,
Morteza Khaberi¹, Jafar Hossinchi⁶ and Reza sehizadeh¹

¹Department of Veterinary pathology, Islamic Azad University Tabriz Branch, Iran.

²Cellular and Molecular Biology Research Center, Shaheed Beheshti University M.C., Tehran, Iran.

³Department of Anatomical Science, Tabriz University of Medicine Science, national management center for health [NPMC], Tabriz, Iran.

⁴Department of Pharmacognozy Tabriz University of Medicine Science, Iran.

⁵Islamic Azad University, Central Unit, Iran.

Accepted 20 March, 2011

The aim of this study was to investigate the comparative effects of aminoglycosides and fluoroquinolones on testis tissue in rats. Thirty male Wister rats were randomly divided into control (n=10) and experimental (n=20) groups. The experimental groups subdivided into two groups of ten. Each received 5 mg/kg (IP) Gentamicin and 72 mg/kg (IP) Ofloxacin daily for 14 days, respectively; however, the control group just received vehicle (IP). In the fourteenth day, rats were killed and testis tissues were also prepared for light and electron microscopic study. All animals exposed to drugs were seen as depletion of germ cells, germinal cells necrosis, especially in spermatogonia and Leydig cells had an abnormal fibroblast-like appearance, abnormal space between neighbor sertoli cells, mitochondria were lost cristae and vacuolated (none energized), lysosome seen more in cytoplasm of sertoli cells, nucleus of moiled cell was done heterochromatin. Gentamicin and Ofloxacin have negative effects on testis architecture and germinal cells damages rats. Therefore, it is recommended that usage of this drug have harmful side effects on male fertility.

Key words: Gentamicin, ofloxacin, testis, rat.

INTRODUCTION

Infertility is one of the major health problems in couples life, approximately 30% of cases of couple infertility are due to a male factor, more factors can interfere with spermatogenesis such as: Drug treatment, chemotherapy, toxins and environmental factors, can have harmful effect on spermatogenesis and affect sperm normal production (Amann et al., 1986). Some patients requiring assisted conception occasionally show evidence of infection of the male reproductive tract (Oliva et al., 2002). The antibiotic aminoglycosides (gentamicin, neomycin, streptomycin)

and fluoroquinolones (ofloxacin) are routinely used by fertility specialists to treat such bacterial infections occurring prior to *in vitro* fertilization treatment, or when high concentration of leukocytes are present in the semen of these patients, irrespective of microbial evidence of infection. In the laboratory, aminoglycosides and penicillin are commonly used in embryo culture, sperm wash and cryopreservation media for controlling growth of bacteria and fungi (Magli et al., 1996). *In vivo* and *in vitro* genotoxicity studies suggest these antibiotics as safe for therapeutic use (Herbold et al., 2001). However, other studies have demonstrated that they impair significantly both testicular function and structure (Abd-Allah et al., 2000; Demir et al., 2007).

*Corresponding author. E-mail: arashkhaki@yahoo.com. Tel: 0098-9143138399.

Recently we reported that ciprofloxacin, gentamicin, neomycin, streptomycin and ofloxacin caused apoptosis in testis (Khaki et al., 2008). The aim of the present study was to compare the effect of gentamicin and ofloxacin on structural testis by light and transmission electron microscopy in rat.

METHODS

Animal

Thirty adult Wister albino male rats were 8 weeks old and weighing 250 ± 10 g, they were obtained from animal facility of Pasteur institute of Iran. Male rats were housed in temperature controlled rooms (25°C) with constant humidity (40-70%) and 12 h light / dark cycle prior to use in experimental protocols. All animals were treated in accordance with the principles of laboratory animal care (NIH). The daily intake of animal water was monitored at least one week prior to start of treatments in order to determine the amount of water needed per experimental animal. Thereafter, the rats were randomly selected and divided into control ($n=10$) and experimental ($n=20$) groups. The experimental groups are subdivided into two groups of ten. Each received 5 mg/kg (IP) gentamicin and 72 mg/kg (IP) ofloxacin daily for fourteenth days, respectively; however, the control group just received vehicle (IP).

Surgical procedure

In the fourteenth day, the pentobarbital sodium (40 mg/kg) was administered intra peritoneal for anesthesia, and the peritoneal cavity was opened through a lower transverse abdominal incision. Then testis and epididymis were immediately removed. The weights of testis in both groups were recorded. At the end of the experiment, the animals were anesthetized with diethyl ether and killed by decapitation.

Light microscopy

The testis was fixed in 10% formalin and embedded in paraffin. Five-micron thick sections were prepared and stained with hematoxylin and eosin (H and E).

Transmission electron microscopy

For transmission electron microscopy (TEM) the testis samples were cut into piece (2×2 mm) and fixed in 2.5% glutaraldehyde (PH=7.4) for 6-8 h at 4°C . They were washed and post fixed in 2% OsO_4 for 1 h, at 4°C . The tissue was dehydrated through ascending grades of ethanol and embedded in araldite CY212. Semi thin sections ($1 \mu\text{m}$) were cut and stained with toluidine blue. Ultra thin sections (60-70 nm) were cut and stained with uranyl acetate and alkaline lead citrate.

Serum total testosterone

Serum concentration of total testosterone was measured using a double antibody RIA (commercial available kit) from Immunotech Beckman Coulter Company. The sensitivities of hormone detected per assay tube were 0.025 ng/ml (Huang et al., 1995).

Statistical analysis was made using the ANOVA and Chi-square tests for comparison of data in the control group with the experiment groups. The results were expressed as mean \pm S.E.M (standard error of means). *P* value less than 0.05 were considered significant.

RESULTS

Light microscopy

Histopathological study showed that the cycle of spermatogenesis was regular in the control group (Figure 1A). However, in all animals exposed to drugs, depletion of germ cells, germinal cells necrosis was seen in them especially in the spermatogonia as well as evidence of cell debris in lumen and presence of lymphocyte and plasmocyte (Figure 1B). Expansion of interstitial space and intertubular space with vacuolization was developed and Leydig cells had an abnormal fibroblast-like appearance. Fibroblastic degeneration in Seminiferous tubules and congestion in veins appeared increased in all experimental groups as compared with those seen in the control group (Figure 1C).

Transmission electron microscopy

In control group, nucleus of spermatogonia cells were euchromatin (Ea), primary spermatocyte mitochondria seemed normal with cristae (Eb), nucleus was euchromatin and cytoplasm organelles and nucleus of myoid cell were normal (Ec), (Figure 1 Ea, Eb, Ec). In gentamicin group histopathological changes were: Abnormal space between neighbor sertoli cells, mitochondria were lost cristae (none energized), (Fa) Lyzosome seen more in cytoplasm of sertoli cells, nucleus of myoid cell was done heterochromatin (Fb), (Figure 1F). In Ofloxacin group histopathological changes were: Mitochondria were vacuolated and vacuoles were abundant in cytoplasm of primary spermatocyte (Ja), nucleus substances were fragmented in primary spermatocyte and increased germ cell degeneration and condensation of germ cell nuclei. Nucleus was heterochromatin in spermatogonia, endoplasmic reticulum systems were dilated and it seemed first stage of cell damage (Jb). (Figure 1 Ja, Jb). Results of serum total testosterone hormones measurement:

DISCUSSION

Antimicrobial therapy has been shown to significantly affect semen parameters in human and animal models. This effect on spermatogenesis may have a significant impact on patients treated with these agents (Servais et al., 2006). In the present study, all two different antibiotics were tested. Ofloxacin and gentamicin had adverse effect on testis tissue in rats (Erbach et al., 1994). Our prior researches showed that, gentamicin, neomycin and

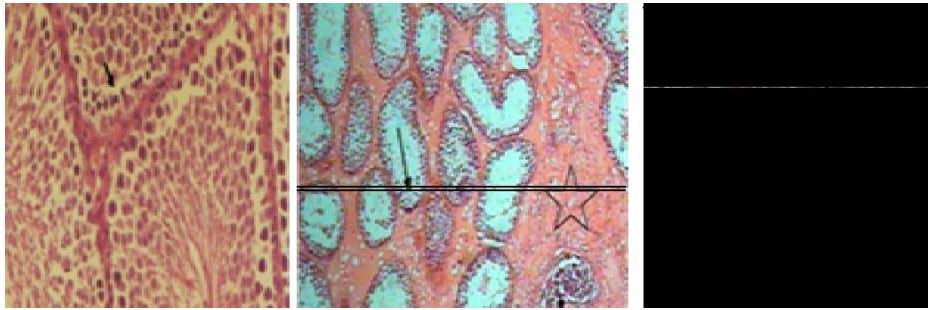


Figure 1. Photomicrograph of testis in control group show regular epithelium seminiferous layers (arrow), H&E (A), X40. Photomicrograph of testis in Gentamicin group show depletion of germ cells, germinal cells necrosis (arrow), and present of lymphocyte and plasmocyte (triangle), Expansion of interstitial space with fibrosis were seen (star) (H and E) method (B), X40. Photomicrograph of testis in Ofloxacin group show expansion of interstitial space (star) with vacuolization of tubular interstitial space in (arrow) (H and E) method (C).

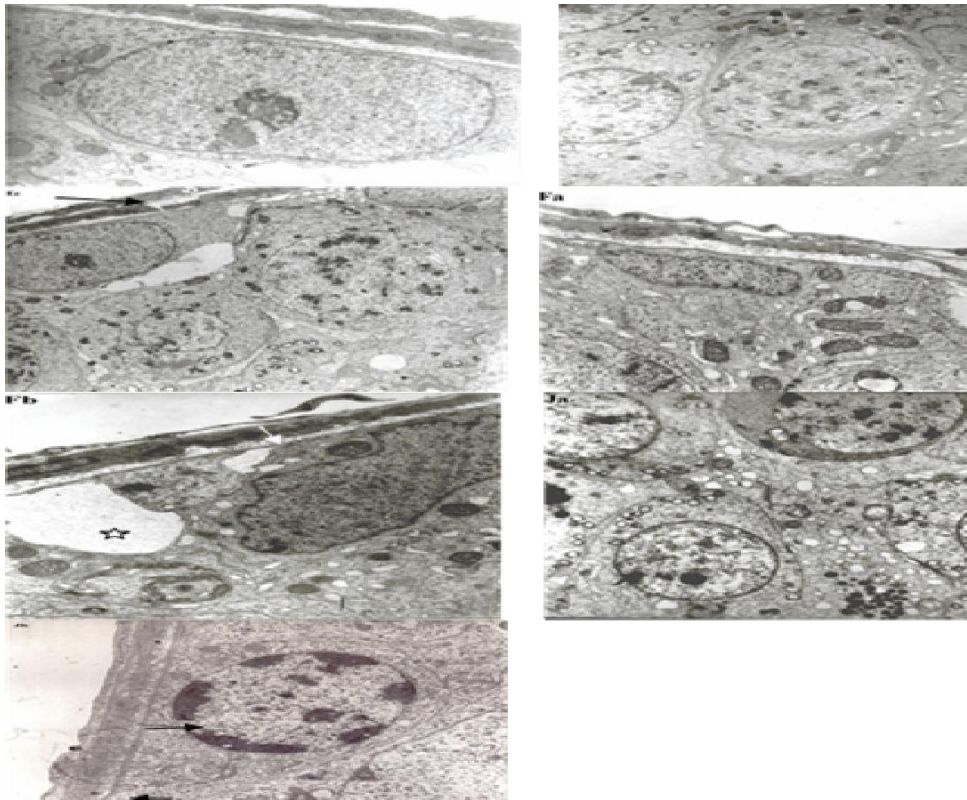


Figure 1 Cont. Transmission electron microscopic (TEM) photomicrograph of testis in control group: Nucleus of spermatogonia was normal seems euchromatin normal (arrow); (Ea), (X5000). Primary spermatocyte mitochondria seemed normal with cristae (arrow); (Eb), (X5000). Nucleus was euchromatin and Cytoplasm organelles and Nucleus of myoid cell were normal (arrow); (Ec), (X5000). (Figure 1: Ea, Eb, Ec). In Gentamicin group histopathological changes were: Abnormal space between neighbor sertoli cells (star), (Fa) (X5000). Lysosome seen more in cytoplasm of sertoli cells, Nucleus of myoid cell was done heterochromatin (arrow); (Fb), (X5000). (Figure 1: F). In Ofloxacin group histopathological changes were: Mitochondria were vacuolated (arrow) and vacuoles were abundant in cytoplasm of primary spermatocyte (Ja), (X5000). Nucleus substances were fragmented in primary spermatocyte and increased germ cell degeneration and condensation of germ cell nuclei. Nucleus was heterochromatin in spermatogonia (arrow), endoplasmic reticulum systems were dilated and it seemed first stage of cell damage (Jb), (X5000). (Figure 1: Ja, Jb).

Table 1. Total testosterone level decreased significantly ($P < 0.05$) in animals received drugs in comparison to control group

Groups	Control	Gentamicin	Ofloxacin
Serum testosterone level (ng/ml serum)	3.6 ± 0.13	1.4 ± 0.06	1.1 ± 0.04

Values are mean ± SE *Significant different at $P < 0.05$ level (compared with the control group).

streptomycin, ofloxacin and ciprofloxacin have negative effects on sperm parameters and cause the testis germ cells to apoptosis in rats; however these side effects are less seen in the streptomycin group (Khaki et al., 2008). Some studies show that ofloxacin at a dose of 72 mg/kg, showed almost the highest potential in terms of impairment of the rat testicular functions (Abd-Allah et al., 2000). It is reported that sperm was significantly decreased after 50 days when ofloxacin was administered to patients in a dose of 200 mg two times daily for 20 days (Andreessen et al., 1995). On the other hand, it have been shown that ofloxacin in rats revealed testicular impairment, indicated by decreased haploid cells at days 11 and 56 from starting the treatment using flow cytometric analysis of testicular aspirate (Crotty et al., 1995). Our study is also comparable to another study who obtained similar results with a slightly different concentration of ofloxacin (King et al., 1997). Moreover, it has been shown that sperm motility was not affected by ofloxacin in a concentration up to 4.5 mg/l as tested on fresh ejaculate of andrologic patients (Khaki et al., 2008; Schramm, 1986). Our light and transmission electronmicroscopic result indicated that all animals exposed to ofloxacin and gentamicin had depletion of germ cells, germinal cells necrosis, especially in spermatogonia, evidence of cell debris in lumen and presence of lymphocyte and plasmocyte. Expansion of interstitial space and intertubular space with vacuolization, degeneration, fibrosis and necrosis of interstitial (Leydig) cells following exudation into the interstices was developed and congestion in veins were increased in all experimental groups, as compared with those seen in the control group and these data's were confirmed by our previous study (Khaki et al., 2008). Testosterone assay showed decreased hormone levels in all drug groups (Table:1) and seems the necrosis of the interstitial cells probably would have resulted in decreased synthesis of this hormone and this was in agreement with Jewell research in 1998. The observed abnormal space between neighbor sertoli cells and heterochromatin nucleus of myoid cell may indicate cooperation sertoli cells and myoid cells in regulative and defensive response and form a barrier to toxic substance of external origin. Oxidative stress plays a critical role in the etiology of defective sperm formation, function; sperm count profile and male infertility (Shen et al., 2000). Some

studies have shown that ciprofloxacin treatment for 15 and 60 days in rats resulted in a marked reduction in sperm parameters (Abd-Allah et al., 2000; Khaki et al., 2008). These results are possibly due to an increased peroxide radical generation in the testis following ciprofloxacin and ofloxacin treatment (Weyers et al., 2002), which then induces DNA single-strand breaks and chromosomal aberrations as demonstrated by *in vitro* genotoxicity studies (Sanchez et al., 2005). It is now well known that gentamicin is severely ototoxic and it seems to be due to oxidative stress (Khaki et al., 2008). Our transmission electron microscopic in gentamicin group showed that mitochondria were lost cristae and lysosome seen more in cytoplasm of sertoli cells, nucleus of myoid cell was done heterochromatin and this has confirmed stage of cell death and agree with other results (Schramm, 1986). Gentamicin is also known to inhibit the activities of phosphatases in the reproductive organs and decrease in sperm count, motility, viability, germ cell apoptosis ascorbic acid, steroidogenic enzymes and cholesterol levels (Andreessen et al., 1995) and decreased antioxidant levels in testis (Narayana, 2008). Histopathological changes such as epithelial cell sloughing, atrophic changes and decrease in germ cell numbers due to cytotoxicity were the factors responsible for decrease in the testis weight and this relationship has been very well established in various other experimental conditions. Degenerative changes in the seminiferous tubules and decrease of spermatozoa in the testis, epididymis and vas deferens are the evidence for genotoxicity.

Degenerative changes in the seminiferous tubules indicate that gentamicin and ofloxacin may directly interfere in the process of spermatogenesis. The increase in germ cell apoptosis and cell damage is possibly due to an increased peroxide radical generation in the testis following ofloxacin treatment (Weyers et al., 2002). In addition, ofloxacin could activate caspases 3 and induce apoptotic pathways. Our results showed that aminoglycosides had an adverse effect on spermatogenesis (Khaki et al., 2008). Studies using rats treated with therapeutic doses of gentamicin confirmed the observations in humans regarding the adverse effects of aminoglycosides on spermatogenesis. These animals were found to have spermatogenic arrest with cessation of spermatogonial division and interruption of meiosis in primary spermatocytes. All antibiotics used in the present study had negative effect on testis tissue, distinct signs that the spermatogenesis process had been arrested or greatly impaired. It has been reported that individually, penicillin, streptomycin and gentamicin did not affect embryo development *in vitro*. However, when penicillin and streptomycin were used together, the percentages of both 8-cell embryos at 58 h and blastocysts at 82 h were significantly lower than the control. In conclusion, gentamicin and ofloxacin antibiotics have negative effect on testis

architectural in rats. Therefore, it is recommended that usage of this drug have harmful side effects on male fertility and cause to increasing infertility risk.

ACKNOWLEDGMENTS

We thank the staff at Islamic Azad University of Tabriz for their help and support in the preparation of this manuscript.

REFERENCES

- Abd-Allah AR, Aly HA, Mustafa AM, Abdel-Aziz AA, Hamada FM (2000). Adverse testicular effects of some quinolone members in rats. *Pharmacol Res.* (41): 211-219.
- Amann RP, Berndtson WE (1986). Assessment of procedures for screening agents for effects on male reproduction: effects of dibromochloropropane (DBCP) on the rat. *Fundam Appl. Toxicol.* (7): 244-255.
- Andreessen R, Sudhoff F, Borgmann V, Nagel R (1995). Results of Ofloxacin therapy in andrologic patients suffering from therapy-requiring asymptomatic infections. *Andrologia* (25): 377-383.
- Crotty KL, May R, Kulvicki A, Kumar D, Neal DE Jr (1995). The effect of antimicrobial therapy on testicular aspirate flow cytometry. *J. Urol.* (153): 835 - 838.
- Demir A, Turker P, Onol FF, Sirvanci S, Findik A, Tarcan T (2007). Effect of experimentally induced *Escherichia coli* epididymo-orchitis and Ciprofloxacin treatment on rat spermatogenesis. *Int. J. Urol.* (14): 268 - 272.
- Erbach GT, Lawitts JA, Papaioannou VE, Biggers JD (1994). Differential growth of the mouse preimplantation embryo in chemically defined media. *J Biol. Reprod.* (50): 1027-33.
- Herbold BA, Brendler-Schwaab SY, Ahr HJ (2001). Ciprofloxacin: *in vivo* genotoxicity studies. *Mutat Res.* (498): 193-205.
- Huang HFS, Linsenmeyer TA, Li MT, Giglio W, Anesetti R, von Hagen J, Ottenweller JE, Pogach L (1995). Acute effects of spinal cord injury on the pituitary-testicular hormone axis and Sertoli cell functions: a time course study. *J. Androl.* (16): 148-157.
- Khaki A, Heidari M, Ghaffari Novin M, Khaki AA (2008). Adverse effects of Ciprofloxacin on testis apoptosis and sperm parameters in rats. *Iran. J. Reprod. Med.* (6): 71-76.
- Khaki A, Ghaffari Novin M, Khaki AA, Nouri M, Sanati E, Nikmanesh M (2008). Comparative study of the effects of Gentamicin, neomycin, Streptomycin and Ofloxacin antibiotics on sperm parameters and testis apoptosis in rats. *J. Biol. Sci.* (8): 35-41.
- King K, Chan PJ, Patton WC, King A (1997). Antibiotics: effect on cryopreserved-thawed human sperm motility *in vitro*. *Fertil. Steril.* (67): 1146-1151.
- Magli MC, Gianaroli L, Fiorentino A, Ferraretti AP, Fortini D, Panzella S (1996). Improved cleavage rate of human embryos cultured in antibiotic-free medium. *Hum. Reprod.* (11): 1520-1524.
- Narayana K (2008). An aminoglycoside antibiotic gentamycin induces oxidative stress, reduces antioxidant reserve and impairs spermatogenesis in rats. *J. Toxicol. Sci.* (33): 85-96.
- Oliva A, Giami A, Multigner L (2002). Environmental agents and erectile dysfunction: a study in a consulting population. *J. Androl.* (23): 546-550.
- Sanchez G, Hidalgo ME, Vivanco JM, Escobar J (2005). Induced and photoinduced DNA damage by quinolones: Ciprofloxacin, Ofloxacin and nalidixic acid determined by comet assay. *J. Photochem. Photobiol.* (81): 819 - 822.
- Schramm P (1986). Ofloxacin: concentration in human ejaculate and influence on sperm motility. *Infection* (14): 274-275.
- Servais H, Jossin YV, Bambeke F, Tulkens PM, Mingeot-Leclercq MP (2006). Gentamicin causes apoptosis at low concentrations in renal LLC-PK1 cells subjected to electroporation. *J. Antimicrob. Agents Chemother.* (50): 1213 -1221.
- Shen H, Ong C (2000). Detection of oxidative DNA damage in human sperm and its association with sperm function and male infertility. *Free Radic. Med. Biol.* (28): 529-536.
- Weyers AI, Ugnia LI, Ovando GH, Gorla NB (2002). Ciprofloxacin increases hepatic and renal lipid hydroperoxides levels in mice. *Biocell* (26): 225 – 228.